



# Workbook

Cases treated by:

**Dr. Ashley Smith**

**Dr. Chris Turnock**

**Dr. David Birnie**

**Dr. David González Zamora**

**Dr. Jamie Reynolds**

**Ormco™**



# Table of Contents

<b>3</b>	Insignia Advanced Smile Design: A History
<b>11</b>	Science of Insignia
<b>15</b>	Best Practices
<b>18</b>	- Treatment Planning
<b>21</b>	- Approver Process
<b>26</b>	- Suggested Wire Sequence
<b>27</b>	Case Studies
<b>29</b>	- Dr. Ashley Smith   Patient: Erin
<b>35</b>	- Dr. Chris Turnock   Patient: Aiden
<b>43</b>	- Dr. Ashley Smith   Patient: Minnie
<b>49</b>	- Dr. David Birnie   Patient: Victoria
<b>57</b>	- Dr. David González Zamora   Patient: Lorena
<b>63</b>	- Dr. David González Zamora   Patient: Natalia
<b>69</b>	- Dr. Jamie Reynolds   Patient: Firas
<b>75</b>	Contributors

# Preface



We are fortunate to exist within a profession where visionaries have a long history of challenging norms and offering new, unique approaches to treatment. In the mid-1980s, Dr. Craig Andreiko, engineer and orthodontist, had an innovative idea to control and minimize the common variables that affect clinical efficiency, therefore achieving reproducible results. With the foresight to see what computers could do for treatment planning and custom appliance design, he would transform digital orthodontics. More than twenty years later, his vision, Insignia, has been used to treat hundreds of thousands of patients all over the world. This pioneering spirit remains at the core of Ormco, and particularly with Insignia. Customized, digital orthodontics is a concept so unique that its evolution is accredited to the visionaries we have been so fortunate to meet, work alongside with and learn from during our lifetime.

This workbook, a work in progress, was developed as an educational tool for all Insignia users. Instead of a how-to manual, it is designed to expose the clinician to the science behind the system, provide best practices and detail a variety of clinical cases. Prepared with this information, users will possess a deeper understanding of the tools and algorithms driving the system.

Our deepest appreciation goes to the teachers, tinkerers, innovators and originals who have had the passion to drive this category of orthodontics to life through Insignia. It is because of you that Ormco is committed to advancing the orthodontic profession through sustained innovation within the digital space. Thank you to those who have contributed to the content and discussion within this workbook and beyond. Dr. Andreiko's legacy and dedication to solving our profession's daily problems was, and continues to be, the driving force behind Insignia's mission.

A handwritten signature in black ink, appearing to read 'Patrik Eriksson'.

**Patrik Eriksson**  
President  
Ormco

# Insignia Advanced Smile Design: A History





**Dr. Craig Andreiko**

Discussions that eventually led to the development of Insignia™ Advanced Smile Design™ were couched in a dilemma. Time: the mid-1980s. Dr. Craig Andreiko, engineer, orthodontist and already the holder of 50+ patents for orthodontic innovations had long been pondering a particular question. As Dan Even,

Ormco president at the time, recalls, “Craig would cite the literature as demonstrating that teeth could be moved safely through bone at a rate of 1 mm per month. So the question he and I had extended conversations about was this: If the vast majority of cases present with no more than 3 mm of tooth discrepancy, why couldn’t we devise a hyper-efficient orthodontic system to treat most cases in no more than three months.”

Of course, Dan Even and Dr. Andreiko recognized that the challenges of tooth movement are many. First are the biological issues. Human beings are complex organic systems. There are tongue, lip and mastication forces, muscular habits, skeletal growth and the periodontal response to name a few. Human aspects aside, there are a myriad of other variables—competing vectors of moving 32 teeth, inefficiencies in the interaction between archwires and bracket slots (including manufacturing tolerances), inaccuracies and inconsistencies in bracket placement, anterior-posterior and vertical discrepancies, tooth shape and size disparities and the human variability relative to the broad averages with which “off-the-shelf” orthodontic brackets and archwires are necessarily designed.

Dr. Andreiko wrote, “Clinical efficiency is all about controlling and minimizing variables to achieve reproducible results and consistent treatment in terms of both time and quality.”<sup>1</sup> He felt the key to meeting the challenges of tooth movement—at least the quantifiable ones—lay in harnessing the burgeoning power of computer technology. What if, he asked himself, he could use the power of the

computer—a technology early in its development at the time—to digitize the anatomy of each individual tooth and its skeletal base, align the teeth into ideal position, then reverse-engineer appliances and a means to bond them accurately on the patient? Wouldn’t such customized treatment be a boon to both orthodontists and patients alike? Dan Even continues, “According to Craig’s thinking, these challenges are all mathematical problems for which computers and their ability to execute sophisticated algorithms are perfect for addressing.”

Having become interested in the clinical applications of the appliances he was designing and with the idea for customized treatment in mind, Dr. Andreiko started working part-time at Ormco in 1983 so he could pursue a dental education. He earned his general dental degree in 1988 and an orthodontic specialty degree in 1991, both from Loma Linda University.

Starting in 1987, he and fellow Ormco colleague and engineer, Mark Payne, began work. Mr. Payne shares the approximate 20 patents for the foundational research behind Insignia. It took nearly three years to write the computer code, develop the algorithms and fabricate and test the measuring devices to conduct their research—an analysis of 200 ideally treated orthodontic patients that would serve as the basis for the development of Insignia. This research, begun in 1991, was the first of its kind in at least two aspects: it was the first to involve actual, ideally treated orthodontic patients and the first to use computer-aided engineering to do so. Dr. Jim Hilgers, retired orthodontist who practiced 30 years in Mission Viejo, California, was also involved with Insignia early in its development and was one of the first orthodontists to bond Insignia cases and offer clinical feedback. As he explains, “The idea was to develop software that would recreate ideally treated orthodontic cases. In essence, Craig and Mark repeated Larry Dr. Andrews’s seminal work of the 1970s, but with ideally treated orthodontic cases rather than ideal naturally occurring dentitions and with more sophisticated, digitized measuring devices.” From this research



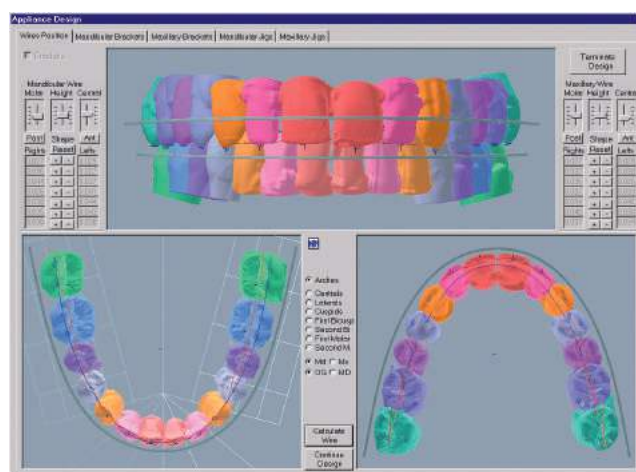
not only was Insignia spawned, the geometries for a greatly refined average twin appliance was born, that of Orthos®, which Ormco launched in 1994.

One of the key differences between Dr. Andreiko's and Dr. Andrews's approaches to appliance design was the development of the archwire shape. Dr. Andrews's mandibular archwire reflects the shape and width of the WALA Ridge. Using this landmark leads to high-profile brackets, particularly in the lower anterior brackets. Mark Payne explains, "With the advantage of computer technology, Craig and I were able to program the software to sweep the archwire shape as close to the teeth as practicably possible. The result was a significantly lower-profile bracket."

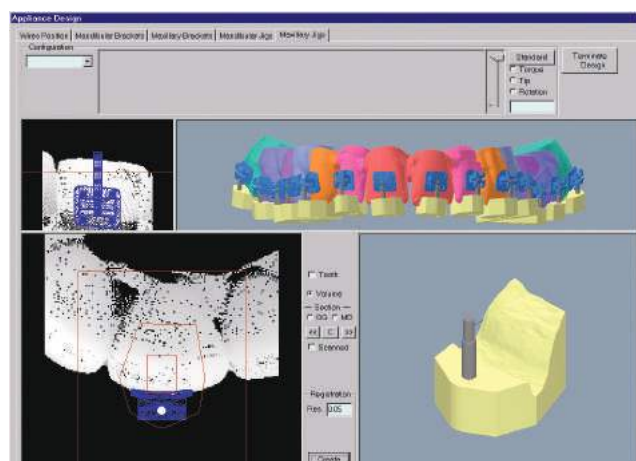
By 1994, Dr. Andreiko had developed the foundational elements of Insignia digital smile design: the concept of the Mantrough—which later evolved to encompass Dr. Dwight Damon's idea of natural arch form development—arch segmentation and dental landmarking, library-dictated root forms and the parameters for custom appliance fabrication—brackets, coordinated archwires and positioning jigs. To these, he added a 3D interactive Approver Interface.

Dr. Andreiko clarified that these ideas "would go beyond, but not dismiss, traditional cephalometric analysis by adding accurate 3D visualization of the desired result and then provide the specific appliances that encourage that result." This concept must also "decrease reliance on hand-eye coordination and, finally, it should improve inter-operator variance."<sup>1</sup>

Dr. Hilgers reminisces that, "Craig focused considerable time and effort in determining what the Insignia arch form should be because he knew that to do an ideal setup and then get custom brackets positioned ideally to drive teeth to that setup, archwires would have to be perfectly coordinated." Dr. Andreiko coined the term "Mantrough" to signify the outline of the mandibular basal bone and its medullary center. He then converted these landmarks into a mathematical equation in which the mandibular teeth would be set so that the crown long axes



Early appliance design software



Early bonding jig design software

would be positioned at specified inclinations. Facial inclinations had been used to date, which had always been problematic. As Dr. Hilgers describes it, "The basic objective, then, was to keep the lower teeth over basal bone, then set the upper teeth to it. I know it sounds simple, but the equations to make all this work together are amazingly complex."

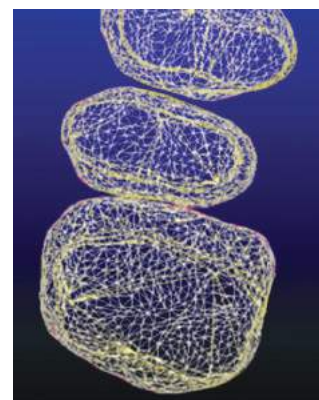
Dr. Andreiko's Mantrough establishes where the apices of the lower roots are positioned. The arch form is dictated by the positions of the crowns.

---

Speaking to the accuracy of Insignia setups, Dr. Andreiko explained, **“Models can contain between 800,000 and one million digitization points in each arch.”**

Because of such dense mapping, individual teeth are often composed of more than 40,000 data points. With this precision, occlusions can be designed and created that are of unprecedented precision and detail.”

---



Whether a clinician prefers the crowns of the teeth be lateral to the apices of the roots (a typical Roth setup) or is a proponent of what Dr. Dwight Damon calls the “natural arch form” with preferences for more upright canines and buccal segments, the Mantrough is the foundation that serves both.

Speaking to the accuracy of Insignia setups, Dr. Andreiko explained, “Models can contain between 800,000 and one million digitization points in each arch. Because of such dense mapping, individual teeth are often composed of more than 40,000 data points. With this precision, occlusions can be designed and created that are of unprecedented precision and detail.” 1


### **Integrating Treatment Plans with Doctor Preferences and Customized Appliances**

The big idea behind Insignia was that it was to be the first system to integrate each clinician’s treatment plan with appliances customized for the individual patient, using computer-aided technology to do so. It would begin by digitizing the skeletal and dental anatomy of the patient (first by scanning PVS impressions and later via direct dental scanning), then proceed to design an ideal setup based on the practitioner’s treatment plan and on algorithms developed to mate the three-dimensional positioning of the dentition to the skeletal framework. Next, the system would design and fabricate brackets, archwires and bracket-positioning devices that would essentially be reverse-engineered from the desired final results for that individual patient. Originally, geometries were cut into the face of the brackets, then with the advent of Insignia SL, the means by which to cut the torque into the base was achieved.

Since Insignia was designed to capture the preferences of the individual practitioner and match these preferences to the specific patient and setup, the system essentially serves as the same appliance the clinician is already using, but with much of the guesswork eliminated. The system allows the practitioner to concentrate more on treatment planning and less on adjusting for the mismatch between the appliance and the patient. As Dr. Bob Ricketts always said, “Begin with the end in mind.”<sup>2</sup> With its 3D visualization software, Insignia allows clinicians to “Begin with the end in sight.”

As Dan Even puts it, “The unique thing about what Craig created is that it didn’t matter which philosophical system you followed, Insignia would offer clinicians a more direct means of achieving high-quality results consistently and reliably.”

Dr. David Sarver, Vestavia, Alabama, thinks that accommodating individual preferences is one of the key appeals of Insignia, “For me, an important aspect



**Original Insignia twin bracket. Customization was milled into the face of the bracket.**



of Insignia is that it can accommodate the various methodologies I employ depending on the needs of the patient. Each clinician's specific proclivities are taken into account."

Dr. Jeff Kozlowski, East Lyme, Connecticut agrees, "Insignia does not determine treatment mechanics nor prescribe tooth movements. It allows clinicians to use the mechanics and adjuncts of their choice. It offers us unprecedented control in determining accurate tooth positions and in making changes directly to the 3D models without relying on an operator's interpretation of instructions."

**The Story: Harnessing the Power of Technology**

Dr. Sarver was intrigued by Dr. Andreiko's work early on, bonding patients from the outset. Dr. Sarver remembers when he initially met Dr. Andreiko, "On my first visit to Ormco and its manufacturing plant, I was introduced to Craig who was sitting at a single desktop computer engrossed in doing some arcane calculations.



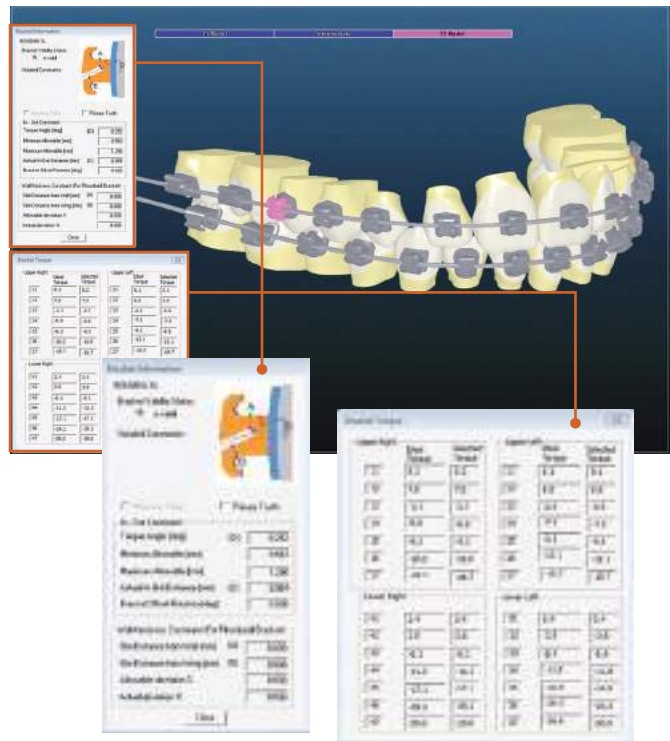
**Dr. Andreiko (right) with Dr. Stephen Tracey (left) and Joshua (center) in Ormco's R&D facility in Glendora, CA. Dr. Tracey treated the first ever Insignia patient at his office in Upland, California.**

He told me what he was working on and I was immediately intrigued—not only by the idea, but by Craig himself. "What a brain. Craig was curious about everything, He thought big thoughts and loved to engage people in big ideas."

Dan Even points out, "Craig's genius was to have had the foresight to see what computers, then in their infancy, could do for customized treatment

planning and appliance design. The challenge was the difficulty of calculating the algorithms given the speed and capacity of computer technology at the time. To afford the project focus, we broadened Craig's team and segregated it from the more conventional appliance research and development efforts. Since applying computer technology to orthodontics had not been done before, Craig had to figure out the algorithms himself." Dr. Hilgers agrees, "The story here is what technology can do when properly utilized and what Craig got done with his brilliance and prescience."

Dr. John R. "Bob" Smith, Winter Springs, Florida, began bonding early iterations of Insignia and continues to serve as an Insignia clinical advisor. "I was an early advocate of variable torque, lecturing and writing about it all through the 1990s. In fact, I had worked with Craig on factoring variable torque into Orthos. One day he and I were chatting about building torque into the Insignia algorithms. I recommended he get out his trusty calculator and make it happen, adding or subtracting torque



**Custom torque chart in design software today**

as needed, letting the Insignia software factor in wire play, wire stiffness and the wire progression. Craig was the genius behind those calculations. I was just the wet-finger orthodontist conferring with him about what we clinicians needed. Patient-specific, per-tooth torque values became one of the foundational elements of Insignia.”

Dan Even recollects, “My mission for the Ormco team was clear—every product Ormco developed must meet three critical standards. It must produce better clinical outcomes, minimize pain and reduce treatment time. With the goal set, Craig was off and running.”

Dr. Sonia Palleck, London, Ontario, Canada, makes this point, “One of Insignia’s key differentiators versus stock appliances is the different torque values it calculates between the left and right sides of the mandibular posterior arch. Teeth erupt asymmetrically. In a great number of cases, there is a maxillary transverse deficiency that causes a mandibular deflection and resultant midline discrepancy. All this leads to teeth being more compensated on one side than the other. The differential torque values Insignia determines can only be measured in fractions of a millimeter, but the distinction between a good finish and a great finish is measured just this way. Insignia is a finishing appliance, which begins at the planning stage. Tooth-by-tooth custom torques are a major factor in getting those high-quality finishes.”

### **What Makes Insignia Different: What it Does for Clinicians and Patients**

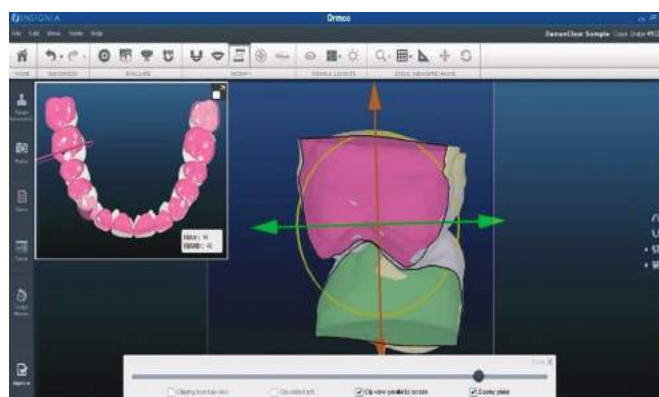
Dr. Kozlowski asked Dr. Andreiko once what made Insignia different, Dr. Andreiko’s reply: “That’s easy. We put brackets on straight teeth.”

Dr. Kozlowski acknowledges, “As we position brackets conventionally, we’re trying to envision how the teeth mesial/distal to it, how the teeth on the opposing side of the arch and occlusally in the opposing arch will be affected. It’s all a mental calculation of how teeth are going to align and how torque is going to be affected, how changing the vertical height of the tooth will change its torque, etc. With Insignia, we can forget about the appliance and focus on designing the smile. We

set the teeth up virtually where we want them—for aesthetics, for the arch development—then Insignia gives us an appliance that gets us there with many fewer adjustments required. Of course, the ideal situation would be no adjustments ever, but

we’re dealing with human beings and variables still too many to calculate—various forces, skeletal growth and compliance to name a few. But even with that, Insignia puts us way ahead in the game.”

Dr. Jamie Reynolds, Novi, Michigan, began using Insignia in 2009 and now lectures on Insignia internationally. He considers the occlusogram in Insignia’s Approver software a good example of



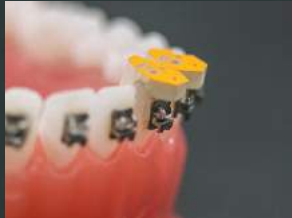### **Occlusogram feature in Approver software**

a feature he particularly relies on to assess case setups and improve the efficiency and quality of his finishes. “Occlusal interferences that usually aren’t obvious until the case gets into Class I position are my number one finishing challenge. If my positioning with stock brackets is off or the geometries are insufficient, vertical occlusal interferences become a time-consuming frustration. They’re often subtle and difficult to find when the patient is actually in treatment. The occlusogram feature in the Approver software serves to greatly minimize such issues in the planning stage.”

“Moreover,” Dr. Sarver relates, “most orthodontists treat a patient to a “milestone,” then “Moreover,” Dr. Sarver relates, “most orthodontists treat a patient to a “milestone,” then reposition brackets or do some wire bending to achieve the final detailing.

# EVOLUTION OF JIGS

## 1st Generation



Each tooth had a corresponding single jig with a drop-in pin.

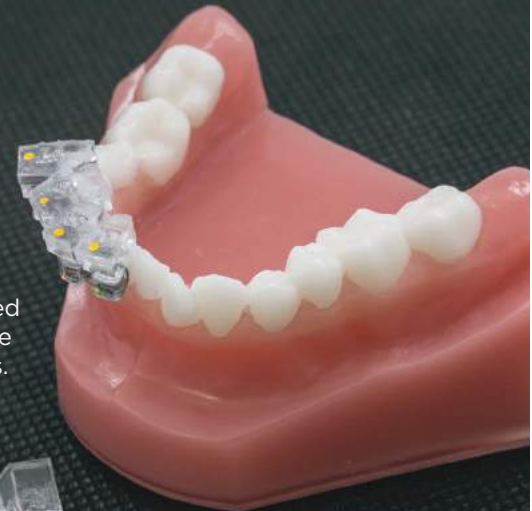## 2nd Generation



2nd generation bonding jigs became available in multi-tooth quadrants.

## Current

4th generation, 3D-printed bonding jigs are available in a variety of quadrants.



While this works in the end, it's hardly efficient. The object of Insignia is to reduce or eliminate this detailing by reducing the bracket placement errors we all experience."

Drs. Kozlowski and Reynolds concur that Insignia has made them better clinicians than they ever would have been without it. Dr. Reynolds remarks, "If you take the time to dive deeply into your case finishes to learn how Insignia works, why it makes treatment more efficient and why they treat out better, it will take your clinical knowledge and skills to a much higher level. Learning why the torque math works the way it does, studying how bracket placement should look and figuring out the patterns for great finishes has taught me to be a better clinician—even with my direct-bonded cases."

Dr. Palleck began using Insignia in 2010, after having used other appliances including a self-ligating appliance from another manufacturer. She now employs Insignia full-time as the standard of care in her practice and is one of the largest providers of Insignia in North America, lecturing internationally about its benefits. "Before using Insignia, there was a percentage of patients I simply could not finish as well as I wanted—not because of patient compliance or diagnosis—it was because with stock appliances, I just didn't have the right prescription. This means I had to

fiddle with the case, adding this, taking away that, struggling to get things to work, sometimes running over time and even accepting a less than ideal result when the patient was tapped out. Insignia's predictability is invaluable in managing a practice. It ensures I deliver the results I promise so I know basically what it will cost to treat a patient. It's a 'fixed cost' for me."

Dr. Reynolds concludes his input with a reference to marketing with Insignia, "I feel leading with customization during a consultation has a greater appeal than leading with a product. People know a lot less about braces than we give them credit for. While off-the-shelf brackets work well enough in certain situations, like anything else across a broader sample, customization is more effective. Today, the call for customization and individuality is at an all-time high. Many people are not only willing to seek out high-tech customized treatment but actually demand such a top-of-the-line option. Adults are all about efficiency, which Insignia offers. Parents especially like it when I talk about designing treatment as unique as their child."

### **Insignia Today. Looking to the Future.**

There have been more than 120,000 cases treated with Insignia, which now boasts advocates in more than 25 countries. The Approver software is continually being refined as are elements of the appliance itself.

In looking to the future, Dr. Smith is inspired not only by what Insignia does for the orthodontist and patient, but by what it might mean for the profession. “Orthodontic residents have always had a challenge finding adequate data on treated cases with which to do research for their theses. With over 120,000+ cases treated to ideal setups, Insignia offers a rich database available to be mined. Moreover, there has never been a large-scale study of treatment results based on ideal setups because such data has never been available. Research using Insignia data could satisfy innumerable questions that have heretofore only been answered by empirical observation. What’s the best average torque for canines? What are the statistical variations in tooth anatomy? What role does ethnicity play? Is there data to validate the natural arch form? The profession has more and more insisted on evidence-based conclusions. To me, Insignia is the mother of inventions that will supply the data to move the profession in this direction. Residents should be all over this!”

Dr. Sarver sums up his ideas about Insignia this way: “I would recommend the system to others because of my appreciation of the ability to design treatment as individually as possible rather than using a “one size fits all” approach. Insignia allows us to plan treatment with the end in mind. With conventional treatment, we put brackets on crooked teeth and in the end sort it out. Insignia allows me to see the teeth straightened in the virtual setup, and brackets, then designed to be placed on ‘straight teeth’

### Acknowledgments

Thanks goes to Drs. Hilgers, Kozlowski, Palleck, Reynolds, Sarver, Smith and Larry White as well as Dan Even and Mark Payne for providing material for this history—not only for which they are directly quoted but for much of the background material.

### References

- 1 Andreiko, C. Increasing clinical performance with 3D interactive treatment planning and patient-specific appliances. Ormco (2014). Orange, CA.
- 2 JCO Interviews Craig Andreiko on the Elan and Orthos Systems, J. Clin. Orthod. 28:459-468, 1994.

in the desired final relationship with a ‘straight’ wire. The key to quality is consistency, and, at the end of the day, the ability to visualize treatment from beginning to end before I start allows me to consistently see conflicts and hazards ahead of time, thus improving my navigation of treatment.”

### Conclusion

When Dr. Andreiko—who always insisted on being called Craig—originally conceived of the idea for customized treatment, it was in response to human variability relative to the limited geometries available for therapy from stock appliances. Considered a genius, usually the smartest person in the room with the biggest ideas and the greatest curiosity, persistent, committed, focused yet amazingly humble, Craig recognized the merits of patient-specific treatment years before personalization became a marketplace expectation. He also shrewdly identified digital technology as holding the potential to achieving what now seems inevitable: the vision and control of digitally assisted case design; the predictability of custom appliances.

According to Patrik Eriksson, Ormco president, “Insignia represents a pioneering technology vital to perpetuating our company’s legacy of innovation. Ormco is committed to continuing the work Craig began nearly 30 years ago—a technological achievement that has established the foundation for improved quality of orthodontic treatment for years to come.”



# The Science of Insignia



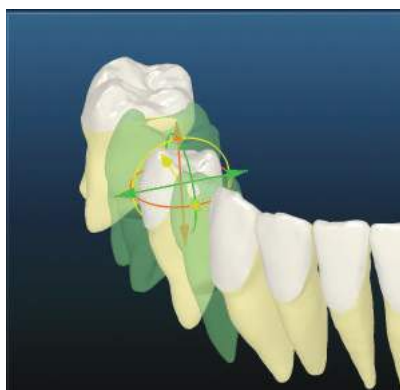
The Insignia Design and Approver software is based on the widely held goal of many orthodontists to provide true straight wire treatment. The key aspects that need to be customized to treat a patient with a true straight wire appliance include:

- **Crown Angulation or Tip**
- **Bracket Positioning – Occluso-Gingival and Mesial-Distal**
- **In-Out**
- **Torque**

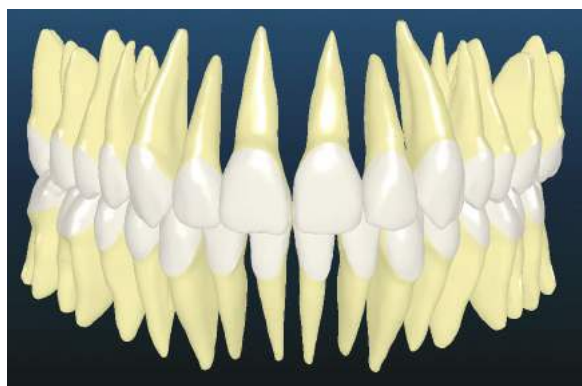Insignia intends to provide a customized appliance to achieve the desired straight wire outcome for each patient through a combination of visual tools controlled by the doctor and algorithmic power embedded in the software.

To utilize the Insignia system, doctors first determine the treatment goal by interacting with the visual tools included in the 3D Approver software to design the ideal outcome for their patient. The digital tools included in Approver enable orthodontists to visualize and manipulate various elements of smile design when creating the patient's setup, including marginal ridges, Curve of Wilson and smile arc, for example.

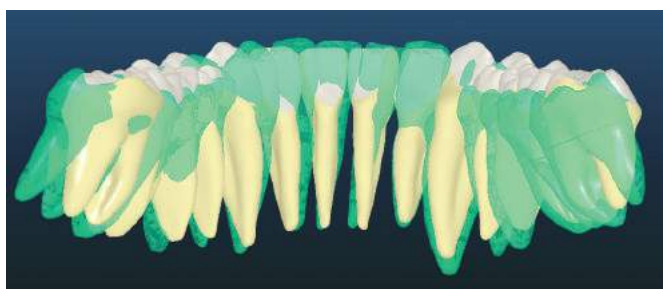
**Marginal Ridges**



**Smile Arc**



**Curve of Wilson**





By using the visual tools and relying on Insignia's algorithms, the doctor is able to manipulate the key aspects of straight wire treatment that inform the final bracket prescription and position.

- **Crown Angulation or Tip:**

Using the compass tool to move the crowns in relation to the flat archwire allows the doctor to see and simulate the ideal finish.

- **Bracket Positioning – Occluso-Gingival:**

The archwire plane defines the bracket position occluso-gingivally for each tooth. The position can be modified by moving the archwire plane itself or moving the teeth in relation to the archwire plane.

- **Bracket Positioning – Mesio-Distal:**

Insignia's algorithm automatically detects the center of each tooth along the facial axis and calculates bracket position mesio-distally. For molars, the buccal tubes may be aligned with the mesial groove of the molar rather than at the center of the tooth.

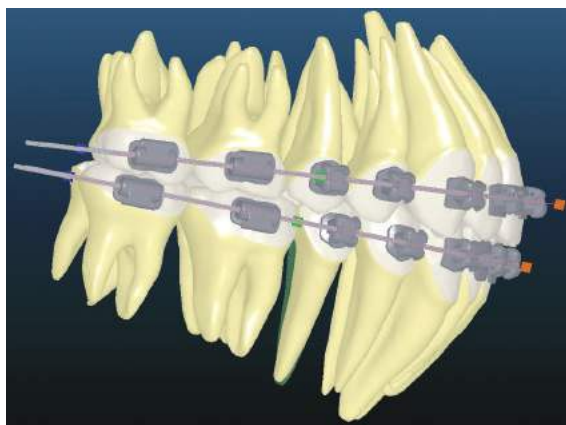
- **In-Out:**

Insignia's algorithm calculates the most appropriate in-out for each bracket to compensate for differences in the crown prominences of individual teeth when the final virtual setup is determined.

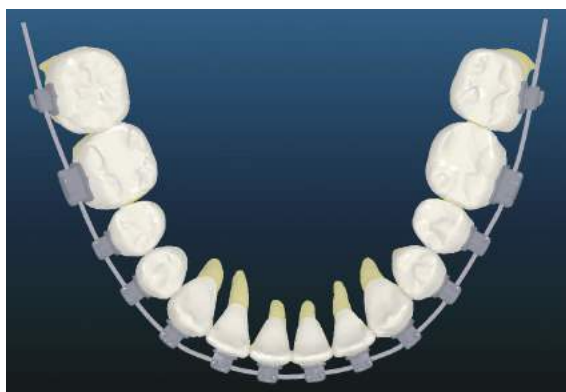
- **Torque:**

Bracket torque is calculated for each tooth individually. Insignia's algorithm analyzes the surface and the inclination of each tooth in relation to the archwire plane, then calculates the torque needed to ensure that the slot of each bracket is parallel to the archwire plane. This provides custom torques for every patient, allowing the doctor to finish each case with a straight archwire and working towards the ideal outcome irrespective of the archwire plane or surface contours of the teeth.

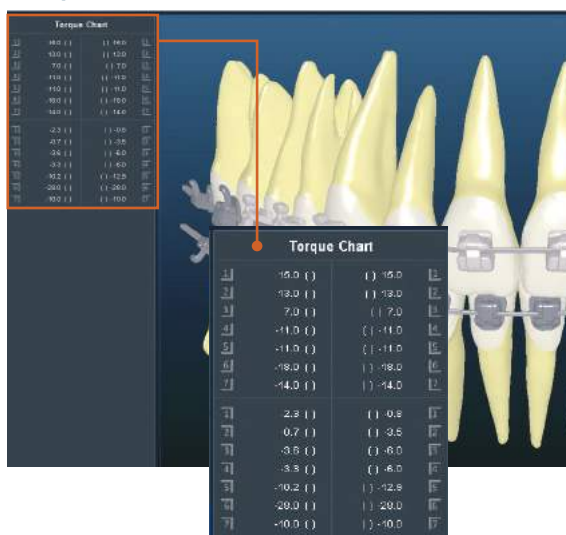
### Archwire Plane



### Bracket Placement



### Torque chart



In addition to the features above related to crown visualization, Insignia offers 3D visualization of the patient's root position, as well as the movement necessary to achieve the desired outcome with parallel roots optimally positioned in the surrounding bone. There are two methods to visualize root position.

CBCT data can be provided with each Insignia case. In this instance, the root information is extracted and stitched together with the crown data via Insignia's TruRoot™ process. By incorporating CBCT root data, there is no need to estimate root position, direction and length. The benefits of accurately planning for root parallelism and the extent of root movement by using actual patient data prior to the start of treatment allows the orthodontist to feel confident in achieving a functional and esthetic result for the patient.

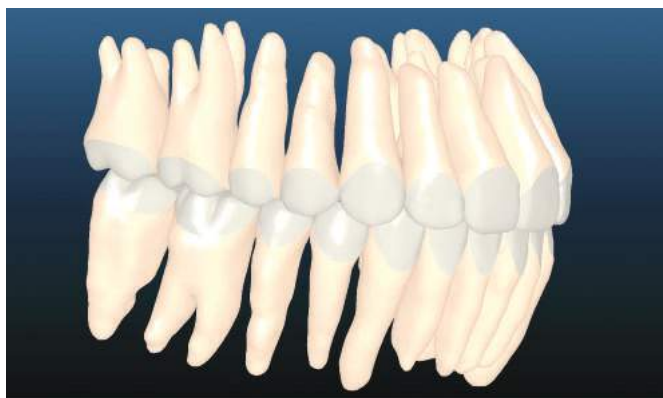If CBCT data is unavailable, Insignia supplies library roots for each case. The library roots are estimated 3D root positions based on Panoramic X-rays provided by the clinician. The library roots can be used for visualization and planning optimal root movements.

With both CBCT root data and library roots, the superimposition tool in Approver allows doctors to accurately visualize the extent of root and crown movement needed to achieve the planned end result.

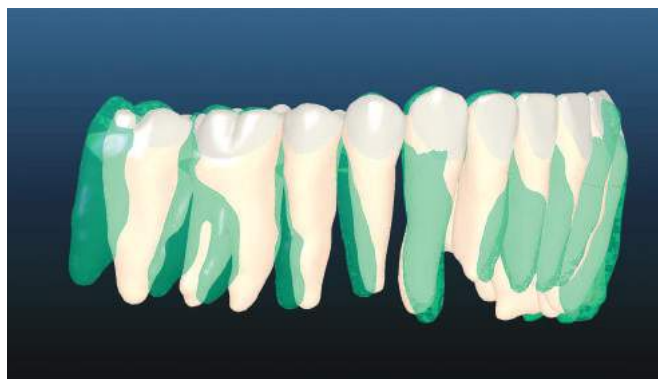
Once the clinician has utilized Insignia's tools to review crown and root positions and movement, and approves the virtual setup, custom fabrication of the appliances begins. Each bracket and archwire is individually machined and indirect bonding jigs are produced to help ensure that each bracket is transferred easily and positioned precisely according to the approved setup.

This overview of Insignia's unique technology demonstrates the importance of achieving an ideal virtual setup and ensuring that the clinician reviews it with great care prior to approval. Taking advantage of the visual aids, case design tools and algorithms that the Insignia system provides, while following the Best Practices outlined in the following chapter, will help clinicians achieve the most favorable results for their patients.

### CBCT Roots



### Superimposition



# Best Practices

Treatment Planning

Approval Process

- Step 1: Preliminary Review
- Step 2: Evaluation and Modification
- Step 3: Verify Proper Alignment
- Step 4: Evaluate Occlusion & Occlusal Contacts
- Step 5: Appliance Check

Suggested Wire Sequence

## Best Practices

# Treatment Planning

Insignia case designers are trained to follow a standard set up protocol that is based on Andrews Six Keys and to follow the general preferences included with every case submission. In order to ensure that the case set up best matches your treatment plan for each patient, we recommend utilizing the 'Outline Treatment Plan' section to provide additional information that is not obvious to the case designer.

### The top items to include are:

1. A/P movement of molars or individual arches
2. Vertical movement of teeth within an arch (Intrusion/extrusion in relation to an ideally positioned tooth) specially the central incisors and first molars
3. Movement planned to achieve:
  - a. Space closure for extraction or pre-existing spaces
  - b. Space opening for veneers, composites, implants, or missing teeth
  - c.
  - d. Directional movement to correct midline
4. A/P movement of molars or individual arches
5. Directional movement to correct midline
6. Placement of the upper archwire plane (for open bite and deep bite cases)
7. Upper central incisor torque (maintain, procline, or retrocline)
8. Lower incisor torque (maintain, procline, or retrocline)

### These movements can be described in several ways:

#### 1. As an absolute value

Examples:

- a. Move upper molars 1mm distal and move lower molars 3mm mesial to achieve Class I
- b. Place upper arch wire plane 5mm from incisal edge of central incisors
- c. Upper midline is correct. Correct lower midline 2mm to the left

#### 2. As a percentage

Examples:

- a. Close the first premolar extraction space by showing 30% mesialization of the posterior and 70% distalization of the anterior
- b. Display 50/50 A/P movement to correct class

#### 3. In relation to ideally positioned teeth

Examples:

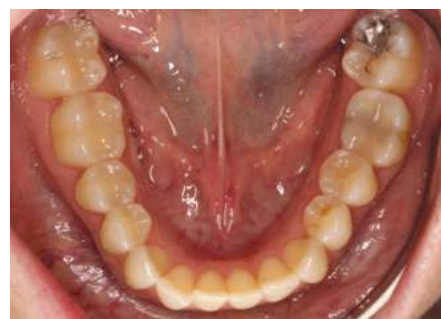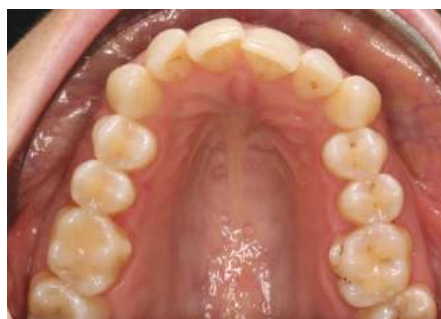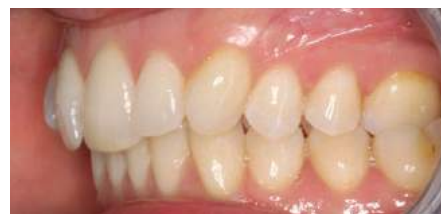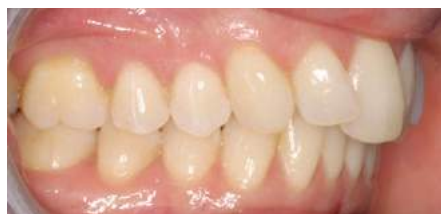- a. Hold premolar heights and intrude molars to the same level
- b. Level upper anterior teeth to the height of tooth 21 to achieve an ideal smile arc

## Example 1

### Outline Treatment Plan

(Please add all your case specific notes here. Do not handwrite notes)

Upper molars should move approx. 2mm distal and lower molar should move approx. 2mm mesial. Hold height of 21 to preserve smile arc. Patient midline is correct. Correct Curve of Wilson and expand arches. Will accept residual buccal overjet and Class II buccal segments due to lack of growth.



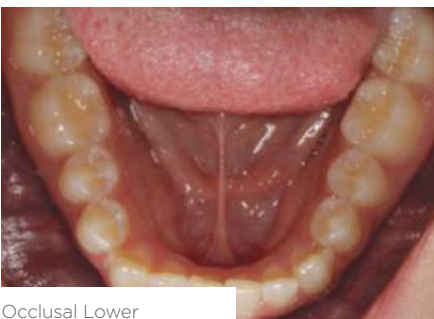
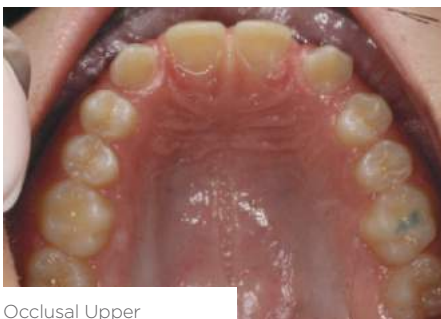
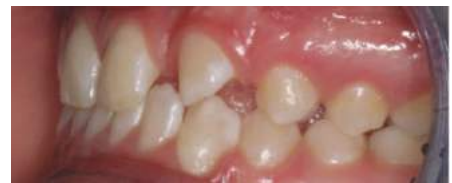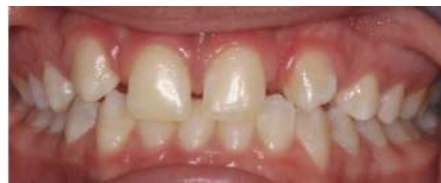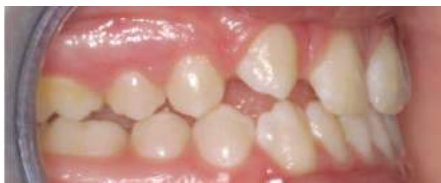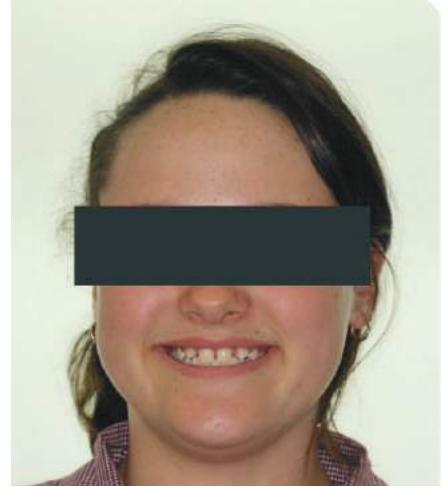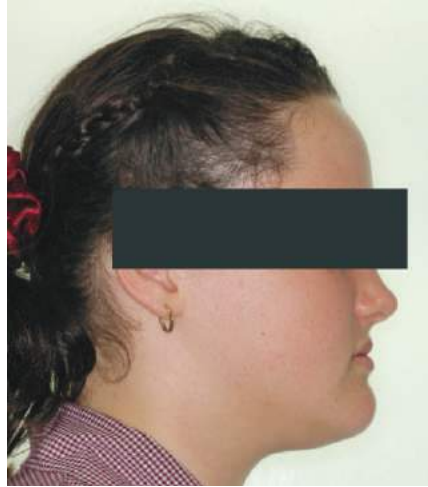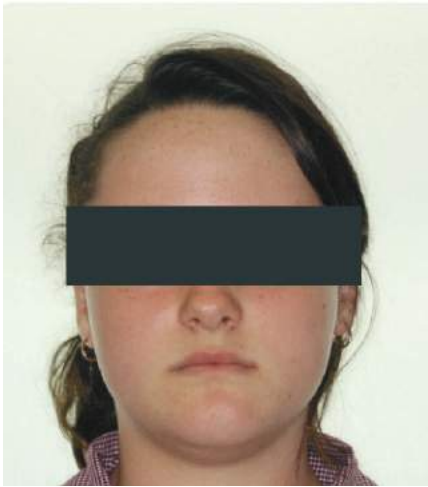## Example 2

### Outline Treatment Plan

(Please add all your case specific notes here. Do not handwrite notes)

Avoid IPR. Upper wire plane needs to be 7mm from incisal edge. Upper centrals need to hold height for smile arc. 16, 26 should advance mesial 6mm using TADs and finish in Class II. Molar position of 36, 46 should not move mesial or distal. 14 and 24 will be intruded 2mm off occlusion.



Occlusal Upper

Occlusal Lower



# Best Practices

## Approver Process

The Approver Guide provides a suggested process for reviewing your Insignia cases. Having a systematic approach should save time, improve consistency, and help you manage cases more efficiently.

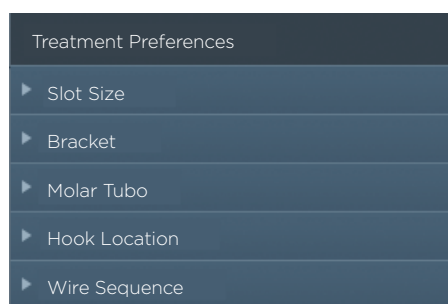
### Step 1 - Preliminary Review

Before making any modifications, review the following items:

#### Treatment Preferences

- Confirm brackets, molar tubes, and wire selection
- Interproximal reduction (if applied)

To make any changes to your preferences, write a note to the technician.



#### Notes



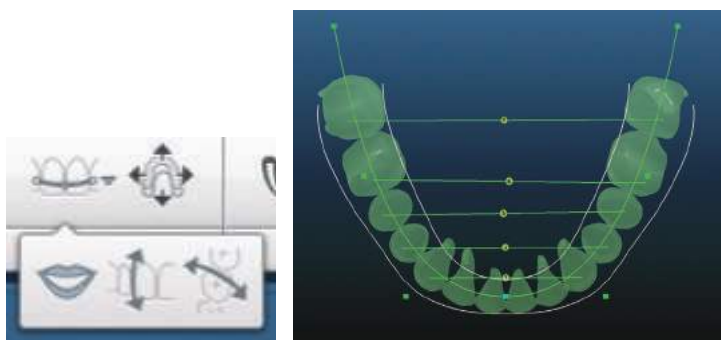
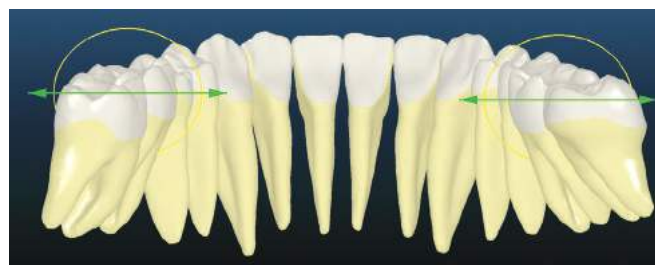
It is important to review the notes each time the case is returned to you. The technician will provide you with information about your setup and provide an alert if any issue exists.

### Step 2 - Evaluation and Modification

#### Expansion & Posterior Torque

**Evaluate** the lower posterior torque, then in-out relative to the mandibular trough. Position the lower arch in a lingual view and turn superimposition 'on'. Posterior uprighting with minimal translation of root apex should be shown.

**Modify** the torque by using the Posterior Expansion (Group-Wise Editing) tool, then **modify** the in-out of the lower arch using the Arch Form tool. Or **modify** by leaving a note for the technician.

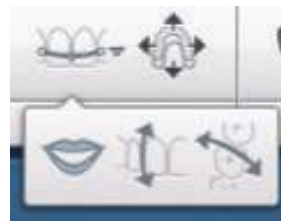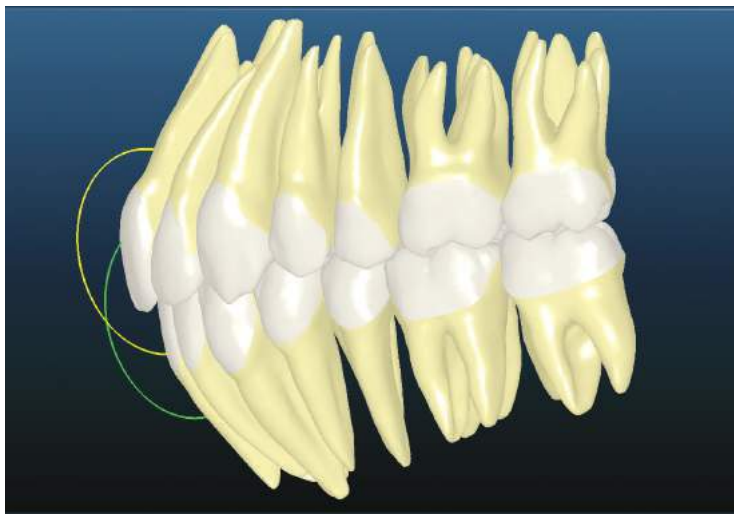


## Step 2 (continued)

### Smile Arc & Incisor Torque

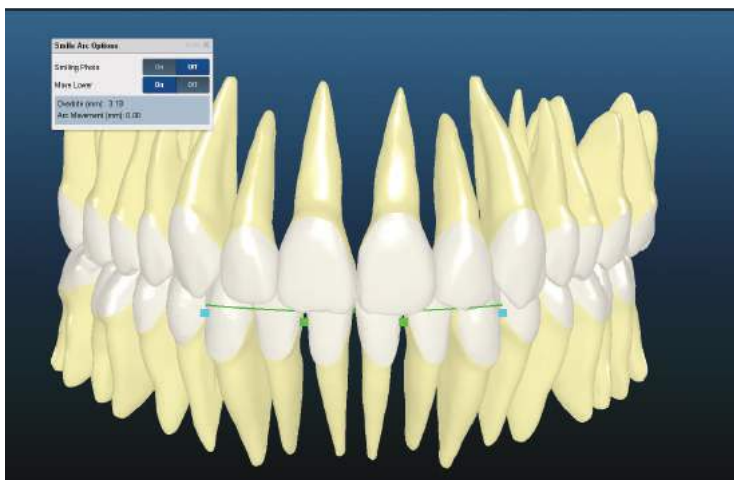
**Evaluate** incisor torque. Reference the patient's photos and cephalometric x-ray (if included).

**Modify** using the Anterior Torque (group-wise editing) tool or by writing a note to the technician.



**Evaluate** the vertical movement of the maxillary incisors. Reference the patient's front smiling photo. Play the movie or toggle between T1 and T2 with superimposition 'on' to determine if the upper incisors move in the desired direction.

**Modify** using the Smile Arc tool or by writing a note to the technician..



**Tip!** The setup has been tilted to simulate an average occlusal plane of 7 degrees. Compare the setup to the patient's cephalometric x-ray to confirm.

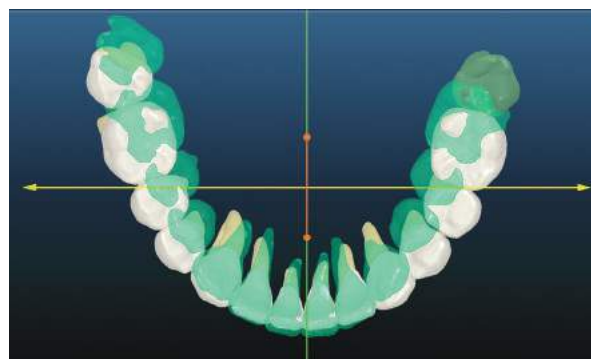
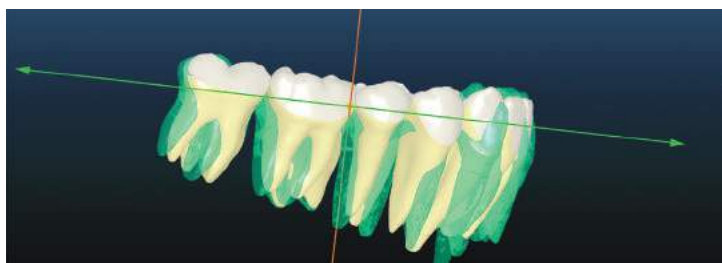
## Step 2 (continued)

### AP Movement

**Evaluate** the directional movement of each arch using the Movie tool or by selecting T2 with superimposition 'on'. It is important that the teeth are moving in the amount and direction that you deem appropriate, as this has implications for mechanics as well as torque compensation.



**Modify** the lower arch using the AP Correction (group-wise editing) tool, then write a note to the technician to adjust the upper arch if needed.



### Submit Changes



If modifications are made in steps 1 or 2, conclude your review at this time. Submit a note to the technician documenting your changes and requesting that the case be "reworked" accordingly.

If no modifications are made in steps 1 or 2, continue with your review to step 3.

**Tip!** Leave a 'note to self' briefly listing the steps you've already completed to prevent repeating any work the next time that the case is returned to you.

### Step 3 - Verify Proper Alignment

**Evaluate** each arch individually to verify proper alignment. Make minor modifications as deemed necessary. If significant discrepancies exist, write a note to the technician for improvement.

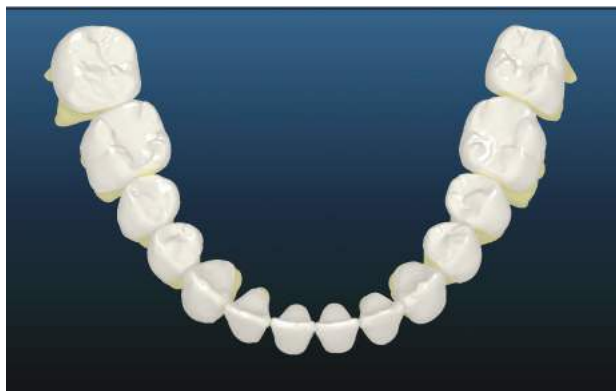**Modify** by double-clicking on a tooth and selecting the desired movement.

Recommended order of movements:

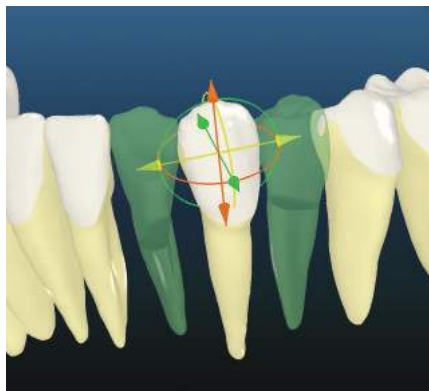
- torque, then vertical
- rotations, then tip (reference the Panoramic x-ray)
- in-out, then mesio-distal

#### Helpful views for evaluating each aspect

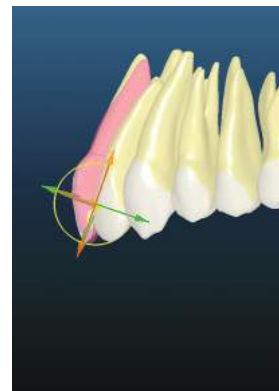
Rotations



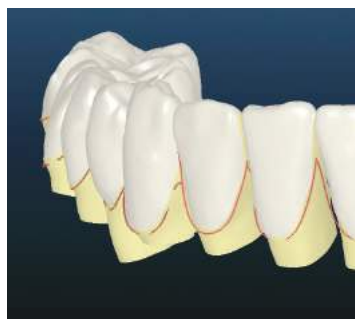Tip



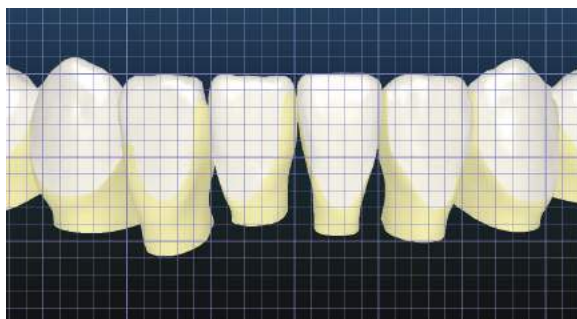
Torque



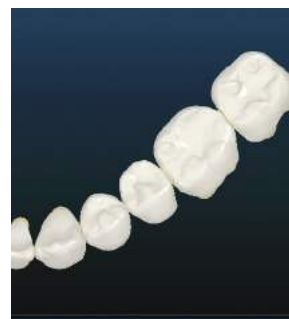Torque



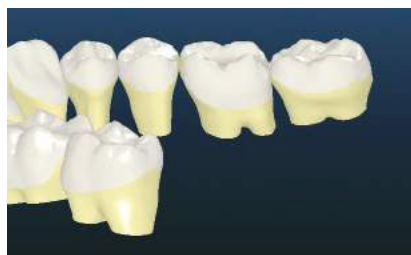Vertical Symmetry



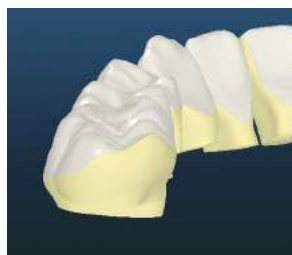
Rotations



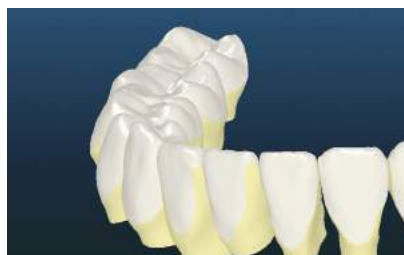Tip



Marginal Ridges



Marginal Ridges



## Step 4 - Evaluate Occlusion & Contacts

**Evaluate** the occlusion by displaying both arches. Consider buccal and anterior overjet, overbite, and overall esthetics.

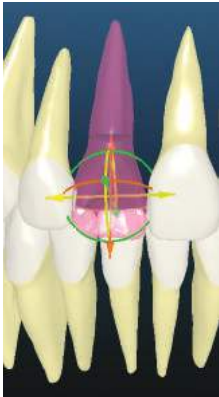
**Modify** by writing a note to the technician. Be specific in documenting the improvements that are needed.

**Evaluate** occlusal contacts by using the Occlusion tool and clipping view. Verify that there are no interferences. If interferences exist, determine if these are due to misalignment or tooth anatomy.

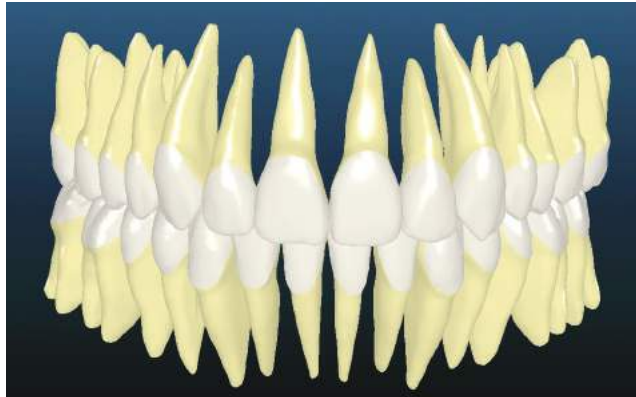

**Modify** by writing a note to the technician. Minor modifications such as in-out, occluso-gingival, and torque can be made within the Occlusion tool by double-clicking a tooth and selecting the desired movement; however if major modification is required, this should be documented in detail to the technician.

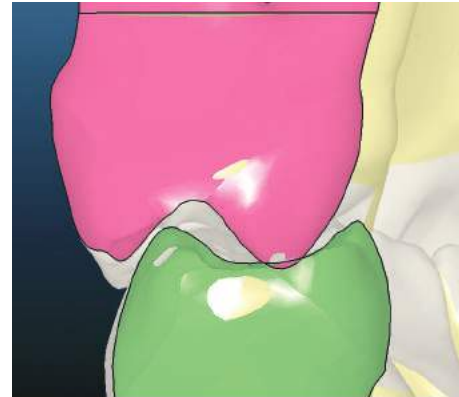
Overbite



Overall Esthetics



Occlusal Contacts



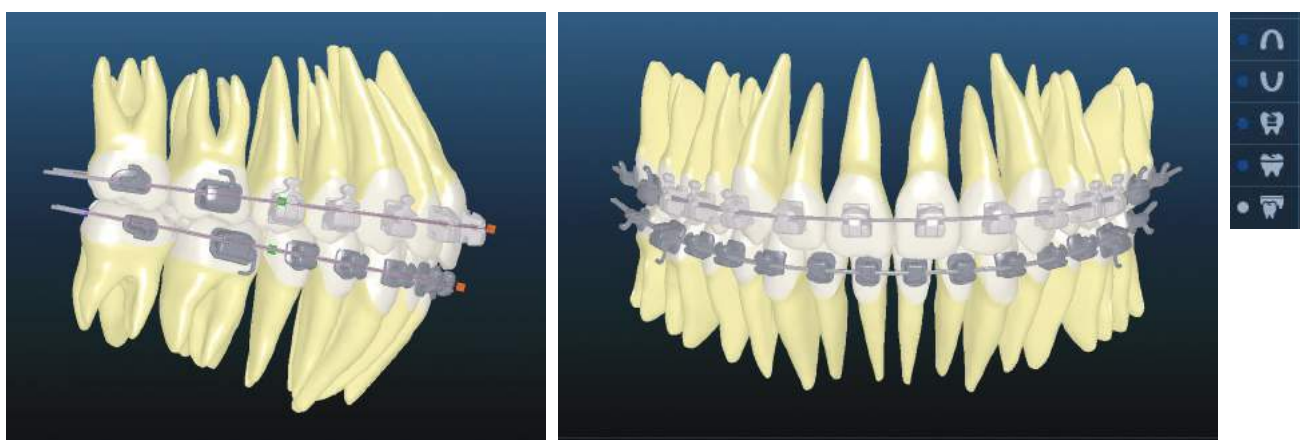
## Step 5 - Appliance check

### Bracket placement

Place the model in frontal and lateral views.

**Evaluate** bracket placement to confirm that there are no occlusal or gingival interferences.

**Modify** by using the Wire Plane tool or by writing a note to the technician.



### Bracket-Torque

**Evaluate** torque chart values. Determine if additional torque is needed to compensate for treatment mechanics.

**Modify** by adjusting tooth position or by writing a note to the technician.

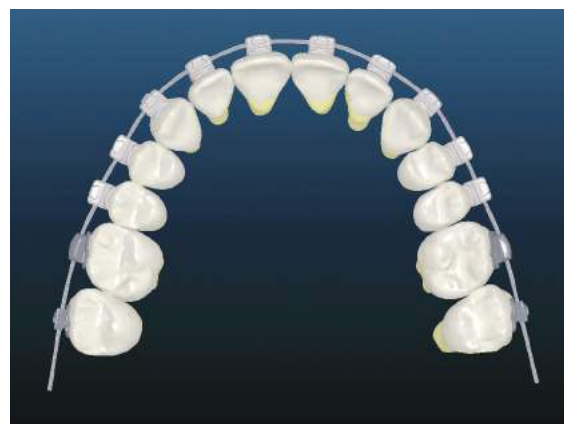Torque Chart			
U1	15.0 ( )	( ) 15.0	U
U2	13.0 ( )	( ) 13.0	U
U3	7.0 ( )	( ) 7.0	U
U4	-11.0 ( )	( ) -11.0	U
U5	-11.0 ( )	( ) -11.0	U
U6	-19.0 ( )	( ) -19.0	U
U7	-14.0 ( )	( ) -14.0	U
L1	-2.0 ( )	( ) -2.0	L
L2	-0.7 ( )	( ) -0.7	L
L3	-3.8 ( )	( ) -3.8	L
L4	-0.3 ( )	( ) -0.3	L
L5	-10.2 ( )	( ) -10.2	L
L6	-28.0 ( )	( ) -28.0	L
L7	-10.0 ( )	( ) -10.0	L

### Arch Wires

Place the model in an upper and lower occlusal view.

**Evaluate** the arch wires to confirm that there are no bends in the wire that will impact treatment. Also confirm that the arch wires are long enough to accommodate unerupted teeth.

**Modify** by adjusting tooth position or by writing a note to the technician.



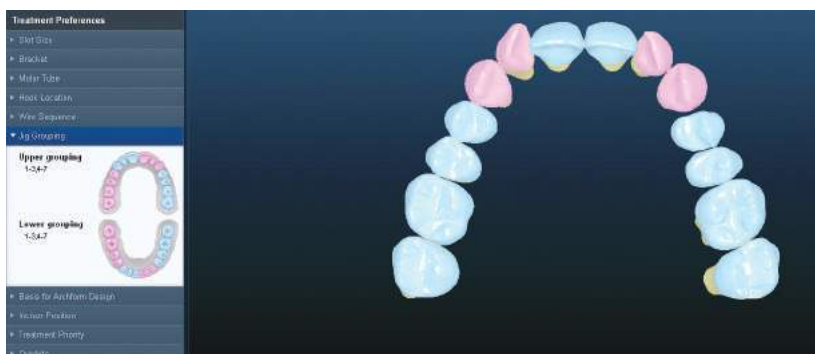


## Step 5 (continued)

### Jig Groupings

**Evaluate** setup in T1 with brackets on. Jig groupings should coincide with your preferences unless an issue exists that results in a single jig being provided.

**Modify** by writing a note to the technician.



### Ready to approve?

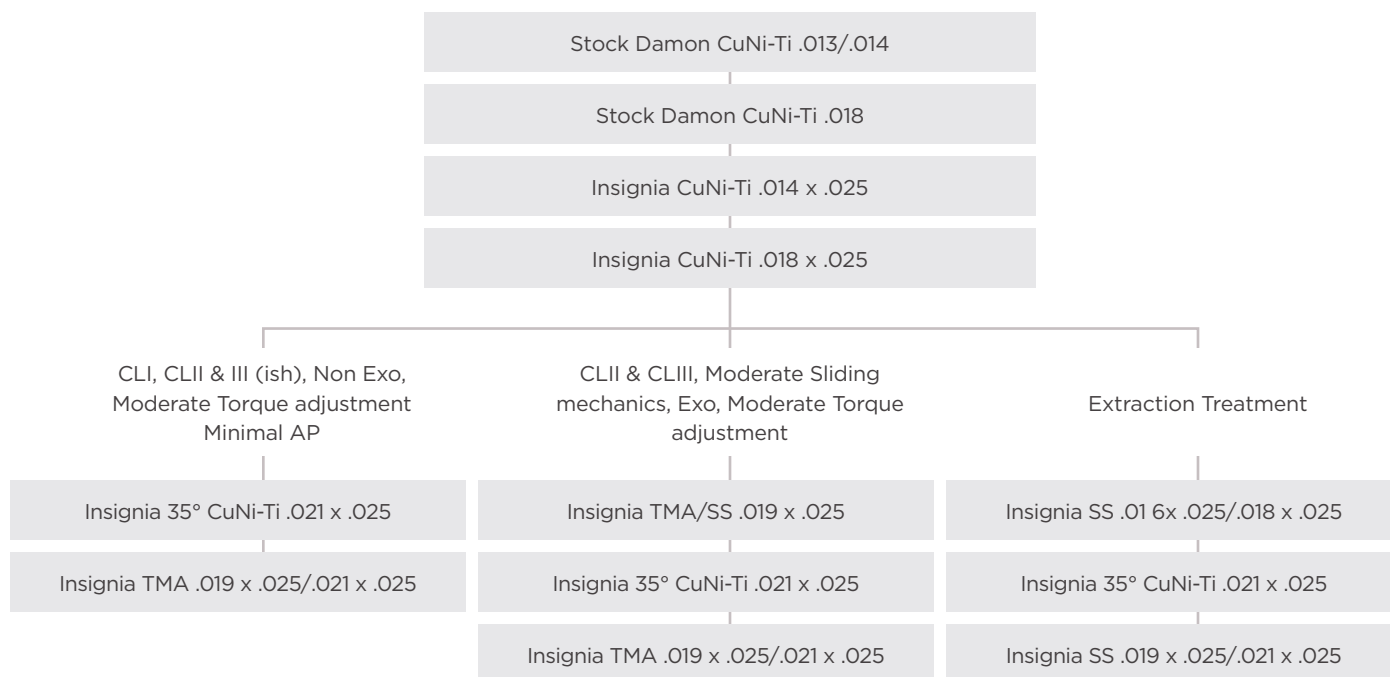


If no further modifications are needed, you are ready to click 'Approve'.

The Approver software will then guide you through a final check of bracket placement and arch wires.

# Best Practices Tip from Dr. Ashley Smith

## Suggested Wire Sequence



### Wire Stiffness Guide

WIRE TYPE	Severe* Malocclusion		Moderate* Malocclusion		Mild* Malocclusion	
	1	2	1	2	1	2
Stainless Steel	.019 x .025		.021 x .025		.025 x .025	
	.021 x .025		.025 x .025		.028 x .025	
TMA **	.019 x .025		.021 x .025			
	.021 x .025					
Copper Ni-Ti * 35° C	.019 x .025					
	.021 x .025					

#### .021 x .025 TMA is...

- ½ as stiff .017 x .025 SS
- 40% as stiff .019 x .025 SS
- And ~ 10% stiffer than .019 x .025 TMA

#### .021 x .025 CuNiTi is...

- 25% as stiff .021 x .025 TMA
- 1/10 as stiff as .021 x .025 SS

# Case Studies

Dr. Ashley Smith | Patient: Erin

Dr. Chris Turnock | Patient: Aiden

Dr. Ashley Smith | Patient: Minnie

Dr. David Birnie | Patient: Victoria

Dr. David González Zamora | Patient: Lorena

Dr. David González Zamora | Patient: Natalia

Dr. Jamie Reynolds | Patient: Firas

**Clinician: Dr. Ashley Smith, Toowoomba, QLD, Australia**

**Patient: Erin**

### Pretreatment Diagnosis

Skeletal Class II, Brachyfacial patient, 13 years old. My chief concern is the traumatic deep bite. Patient already commenced peak growth and lives 2 hours drive from our practice. Skeletal II Brachyfacial. Profile. Lips are retrusive to the nose and chin and have a thin contour. Upper Centrals are over erupted by 2mm and retroclined 25 degrees. Smile arc can be flattened 2mm. 13 is distally angled and 12 and 22 mesial angulation. Gingival heights of the centrals to laterals are incorrect. The proportion of central incisor enamel exposed compared to gingival height is low due to the starting position of the centrals. The upper centrals are over erupted. Incisal edges are not worn or damaged.

### Treatment Plan Objectives

Treat non-extraction using Insignia SL. Develop collapsed arches with Damon mechanics, keeping the occlusion unlocked with • Composite resin, bite ramps on the first premolars.

- Then with the AdvanSync appliance.
- With anterior Bite Turbos after the AdvanSync has been removed. Insignia design will hold the height of the upper laterals and align smile arc.

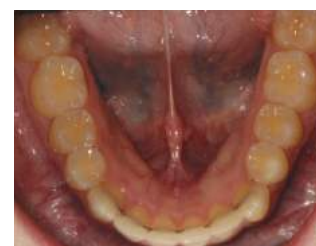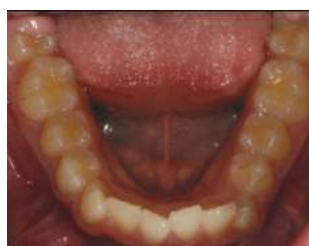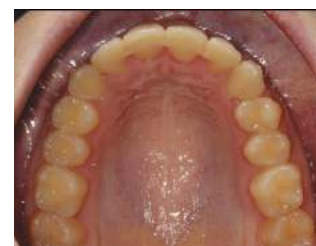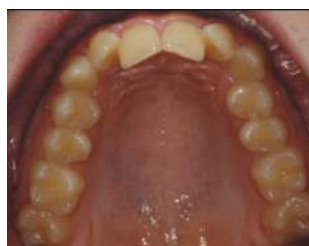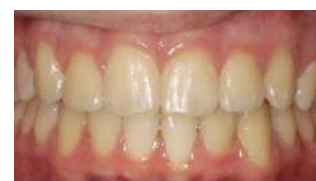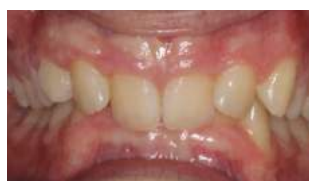The Insignia overlays must show the 36 46 moving mesial 3mm and the arches expanding as the curve of Wilson is levelled.

**Appliance used:** Insignia SL

Initial



Final



## Treatment Sequence

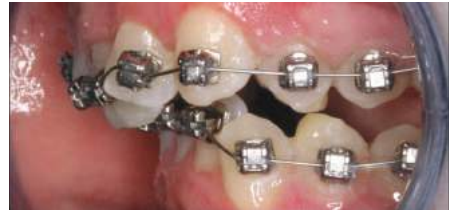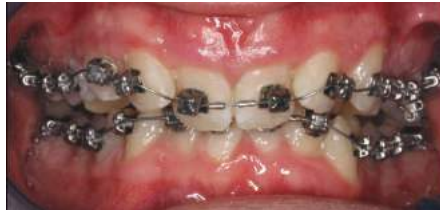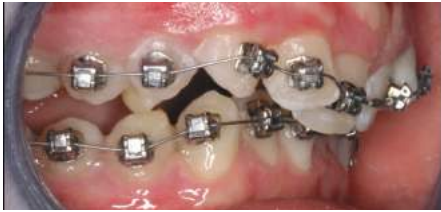Appointment	Archwire	Notes
<b>1</b>	<b>U:</b> .013 Damon CuNi-Ti* <b>L:</b> .013 Damon CuNi-Ti*	Bonding CR ramp 14 24
<b>2</b>	<b>U:</b> .014 Damon CuNi-Ti* <b>L:</b> .014 Damon CuNi-Ti*	
<b>3</b> 14 weeks	<b>U:</b> .018 Damon CuNi-Ti* <b>L:</b> .018 Damon CuNi-Ti*	
<b>4</b>	<b>U:</b> .018 Damon CuNi-Ti* <b>L:</b> .018 Damon CuNi-Ti*	Separators for AdvanSync
<b>5</b> 22 weeks	<b>U:</b> .018 Damon CuNi-Ti* <b>L:</b> .018 Damon CuNi-Ti*	Fit AdvanSync
<b>6</b>	<b>U:</b> .016 x .025 CuNi-Ti <b>L:</b> .014 x .025 CuNi-Ti	Activate AdvanSync 2mm
<b>7</b> 36 weeks		Activate AdvanSync 2mm (right), 4mm (left)
<b>9</b> 52 weeks	<b>U:</b> .018 CuNi-Ti <b>L:</b> .014 x .025 CuNi-Ti	Remove AdvanSync, Bond all 6's Add ¼ 2oz elastics, Add bite turbos 11 21 Remove CR ramps 14 24
<b>11</b> 60 weeks	<b>U:</b> .018 x .025 CuNi-Ti	Chain upper 3-3
<b>13</b> 73 weeks	<b>U:</b> .021 x .025 35° CuNi-Ti <b>L:</b> .021 x .025 35° CuNi-Ti	Ligate upper 3-3 Elastics (night time only)
<b>14</b> 81 weeks	<b>U:</b> .021 x .025 TMA <b>L:</b> .021 x .025 TMA	Add upper CTBs
<b>15</b>	<b>U:</b> .021 x .025 TMA <b>L:</b> .019 x .025 TMA	Add offsets Retied upper CTBs
<b>16</b> 106 weeks		Debonding, Retention, Upper 2-2 Everstick, Lower 3-3 Flex, Maxillary invisible retainer (night time only)

\*Stock round wire

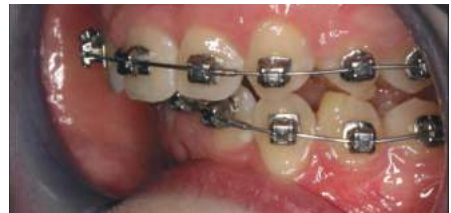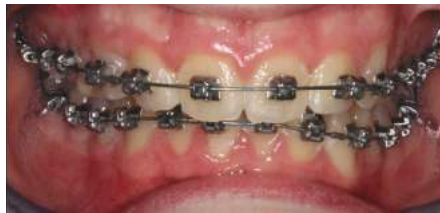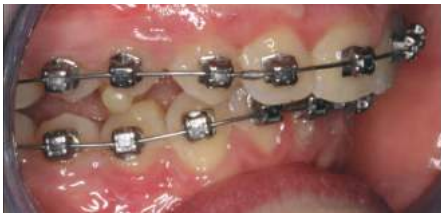 Appointment photos featured in this case study



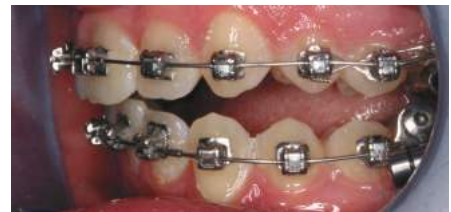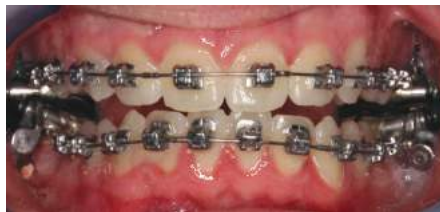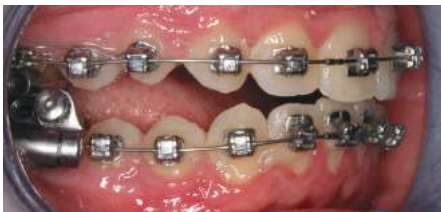**Bonding**



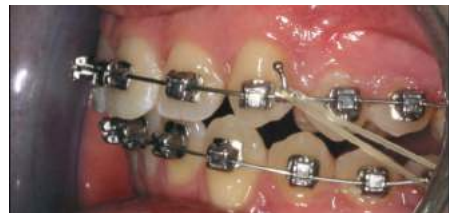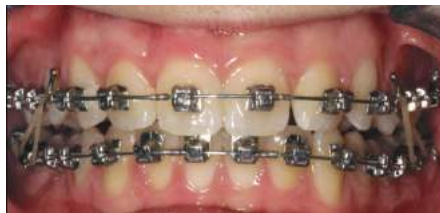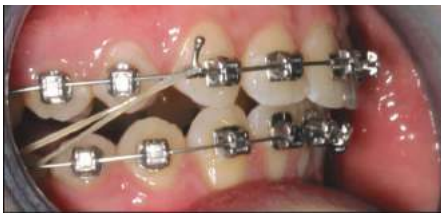**Appointment 3, 14 weeks**



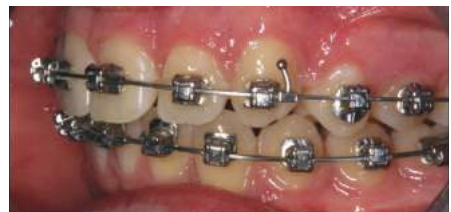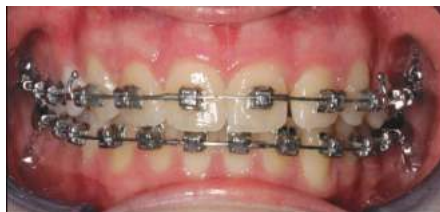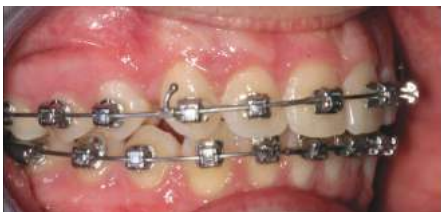**Appointment 5, 22 weeks**



**Appointment 9, 52 weeks**

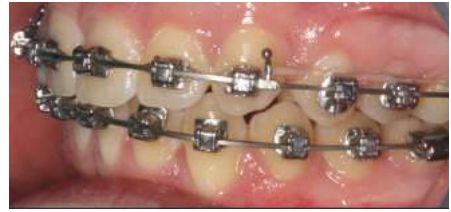
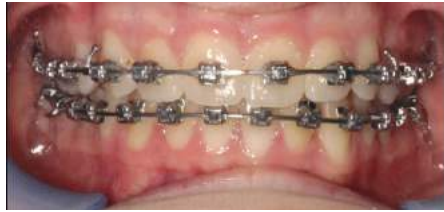
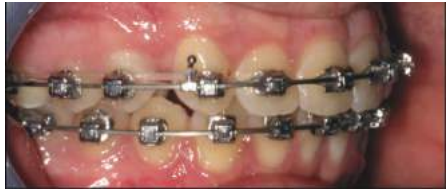**Appointment 11, 60 weeks**

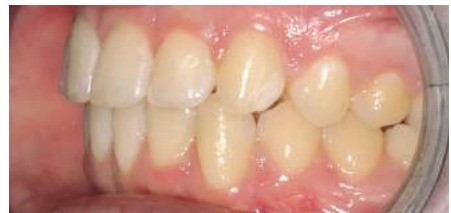
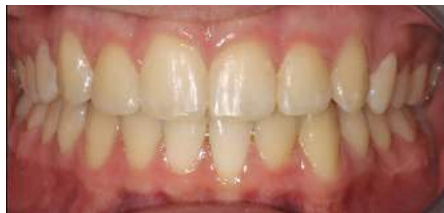
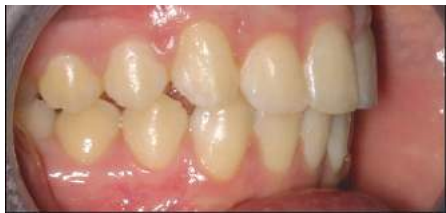

**Appointment 14, 81 weeks**



**Final, 106 weeks**



## Treatment Discussion

All treatment objectives were achieved and the patient is pleased with her orthodontic result. The patient now has improved lip support, and the bite depth and buccal occlusion is much improved.

The incisor proportions and gingival relationships are close to ideal as are the connectors and embrasures.

Ligating the AdvanSync upper first molar crowns to only the upper first premolars, has allowed some distalising of the upper posteriors whilst leaving some overjet to allow for further lower arch advancement. All my AdvanSync cases are treated this way.

Wherever possible I ensure the archwire includes the 7's. Having the 7's all on the archwire helps minimize the intrusion of molars which can be an iatrogenic effect of AdvanSync treatment.

Starting this treatment with U/L .013 Damon CuNi-Ti archwire for 6 weeks then transitioning to only the U/L .014 Damon CuNi-Ti for 4 weeks keeps the forces very light allowing good arch development.

It is also important to keep the deep bite unlocked to assist arch development. In deep bite cases it is important to place anterior bite turbos on the day the AdvanSync is removed and support

## What I Would Do Differently Today

I was happy with my chosen mechanics for this case and I treat a lot of my Skeletal II patients with a similar treatment plan.

Although the aesthetic result is good and the torque of the upper incisors is much improved, on reflection I would have preferred an increase of approximately 5 degrees labial crown torque on the upper incisors. One method that we now use in this practice to more accurately design the ideal final position of these teeth in our Insignia set up is to use a smiling profile picture (in natural head position). This helps to create an incisal position

which matches the patient's facial balance.

One flaw with this case was that too much resin had been left under a few brackets at bond up. The 32, 41 and 11 all had slightly too much resin, and therefore they could not follow the Insignia plan, hence the need to add offsets.

Recently we have purchased a very powerful sand blaster and are much more confident repositioning the Insignia brackets with the single jigs when the initial bondup is not ideal. Another challenge with this case was broken brackets and, since the patient lives more than 2 hours from the practice, they could not attend to have the brackets replaced for about 4 weeks. When rebonding broken first molar brackets I now prefer to use SnapLink as I can step the archwire to compensate for the small in/out distance between Insignia custom and standard bracket. (I may still round the wire to compensate for different torque between a stock bracket and prescribed Insignia bracket torque)

At the 1 month retention check I added an anterior bite plane to the upper essix to aid retention of the deep bite. This has an added advantage of adding rigidity to the upper retainer which helps to maintain the width gained during treatment. I recommended the upper bonded stay in place for at least 2 years, when it eventually fails, I remove it. The existing essix will still fit and retain. The flex L3-3 I advise is to stay as a permanent retainer.

**Dr. Chris Turnock, Toowoomba, QLD, Australia**

**Patient: Aiden**

### Pretreatment Diagnosis

Meso- to dolichofacial Class II skeletal base, with an associated Class II div 1 subdivision Right malocclusion. Significant mandibular retrognathia and lack of effective chin projection. Lip strain evident. Family history of Class II skeletal base. Mild upper and lower incisor proclination with mild crowding in both arches. Impacting 8's.

### Treatment Plan Objectives

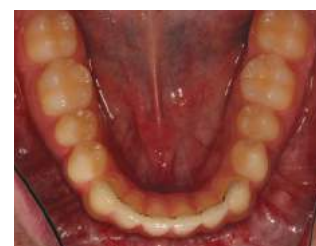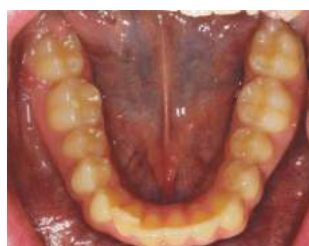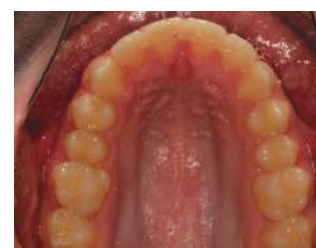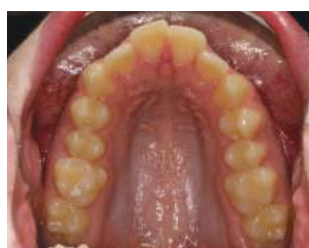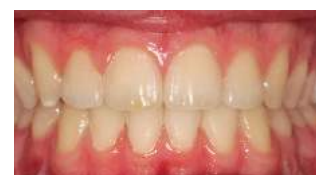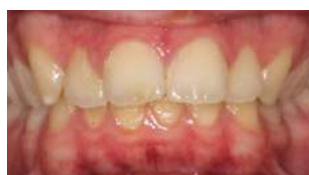- Treatment aims were to relieve the crowding in both arches, decompensate the dentition for orthognathic surgery. Expand the arches in the premolar region to help fill the buccal corridors. Restore facial balance via orthognathic surgery.
- Treatment Plan notes submitted with this case:
- Try to avoid IPR, if required limit to .25mm mesial of 33, 32, 42, 43
- Upper wire plane to be about 5mm from incisal edge
- Upper centrals need to maintain current height
- Molar movements should be finishing Class I
- Please turn off A-P Torque Compensation as this is a surgical case
- Class II correction will be via mandibular advancement
- Ensure all lower incisor brackets are clear of upper incisors
- Midline Correction- Correct lower midline at surgery
- Preserve smile arc

**Appliance Used:** Insignia SL

Initial



Final



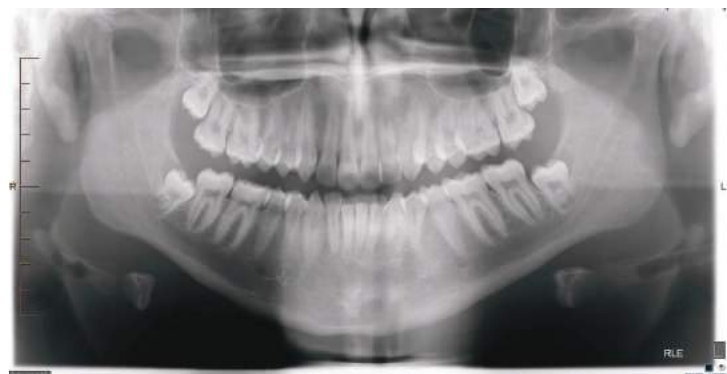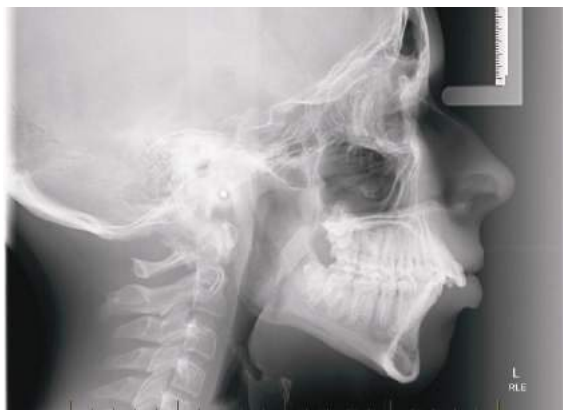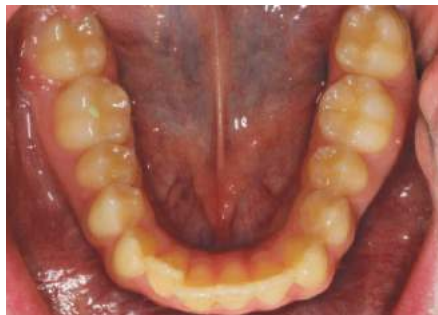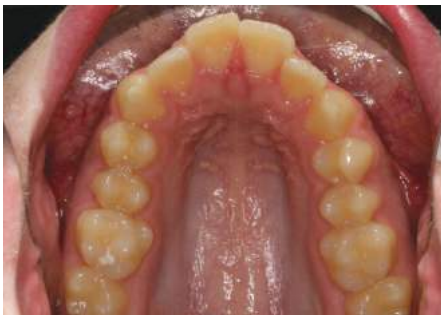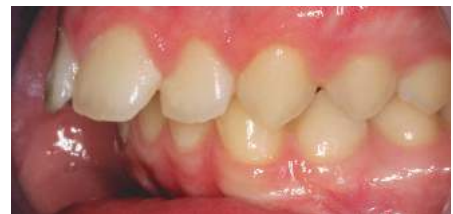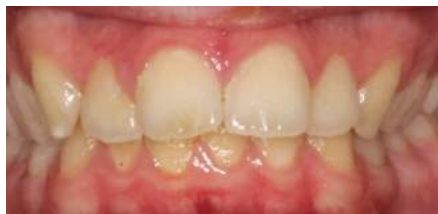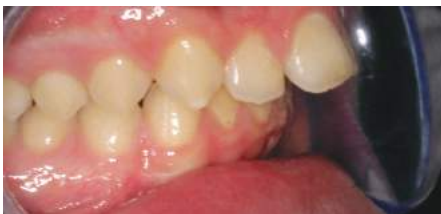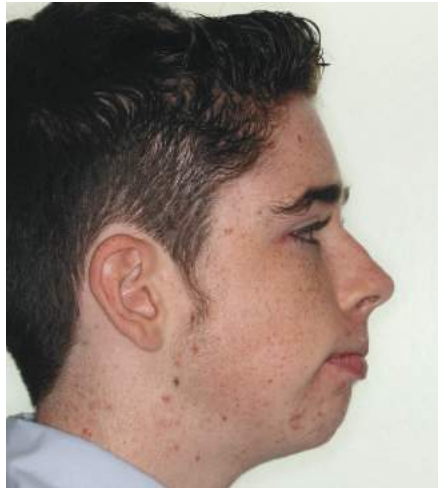## Treatment Sequence

Appointment	Archwire	Notes
<b>1</b>	<b>U:</b> .014 Damon CuNi-Ti* <b>L:</b> .014 Damon CuNi-Ti*	Bonding Composite stops for bite opening/disarticulation
<b>2</b> 5 weeks		Scheduled wire trim
<b>3</b> 11 weeks	<b>U:</b> .018 Damon CuNi-Ti* <b>L:</b> .018 Damon CuNi-Ti*	Removed CR stops
<b>4</b> 15 weeks	<b>U:</b> .016 x .025 CuNi-Ti <b>L:</b> .014 x .025 CuNi-Ti	
<b>5</b> 23 weeks	<b>U:</b> .018 x .025 CuNi-Ti <b>L:</b> .018 x .025 CuNi-Ti	
<b>6</b> 30 weeks	<b>U:</b> .021 x .025 35° CuNi-Ti <b>L:</b> .021 x .025 35° CuNi-Ti	Chain L 6-6 under arch wire
<b>7</b> 38 weeks	<b>U:</b> .021 x .025 TMA® <b>L:</b> .019 x .025 TMA®	Started Class III 3/16 4oz elastics full time
<b>8</b> 47 weeks		Impressions for Surgeon for surgery
<b>9</b> 56 weeks		Checked elastics, keep going with them Plan for new OPG and Let Ceph to view at next appointment
<b>10</b> 64 weeks		Checked x-rays New impressions for surgeon at surgeons request. Added upper chain tie backs. Go to night only wear for Class III elastics
<b>11</b> 67 weeks		Breakage 27, new bond with spare insignia bracket, and dropped back to U .021x.025 35 degree CuNi-Ti

Appointment	Archwire	Notes
<b>12</b> 69 weeks		Keep going with night time only Class III elastics Refit Upper .021 x .025 TMA Very Small Offset 11, 21 Booked Surgery for 27th June 2015
<b>Prä-OP-Termin</b> <b>13</b> 74 weeks		Surgery booked after this visit. Added surgical hooks to arch wires
<b>Post-OP-Termin</b> <b>14</b> 76 weeks		Checked elastics post-surgery, advised to persist with the heavy elastics
<b>15</b> 78 weeks		Check elastics, keep going with them Expand upper arch wire
<b>16</b> 82 weeks		Bond button on lingual of 26 for cross elastic 3/16 4oz left side cross elastic full time and 1/4 4oz night only box elastics left and right
<b>17</b> 84 weeks		Check elastics, keep going with them
<b>18</b> 85 weeks		Stop cross elastic Chain U 3-3 under archwire Keep going with 3/16 4oz left and right
<b>19</b> 88 weeks		Check elastics, keep going with them, book debond appointment
<b>20</b> 89 weeks		Removed all appliances. Bonded upper 2-2 (everstick). Bonded lower 3-3 (Flex). clear retainer with wire to hold expansion, plan for new clear retainer with anterior bite plane in 1 month

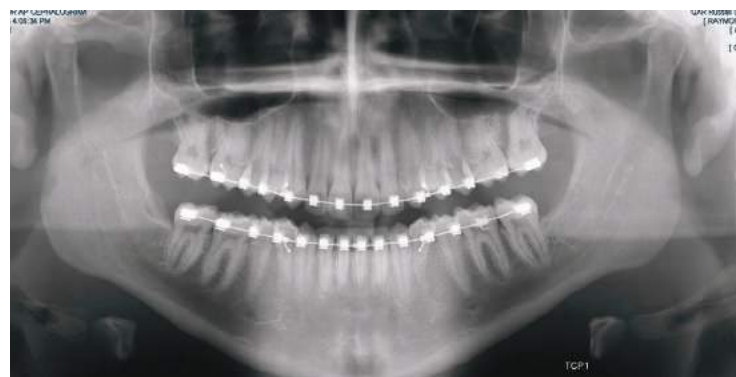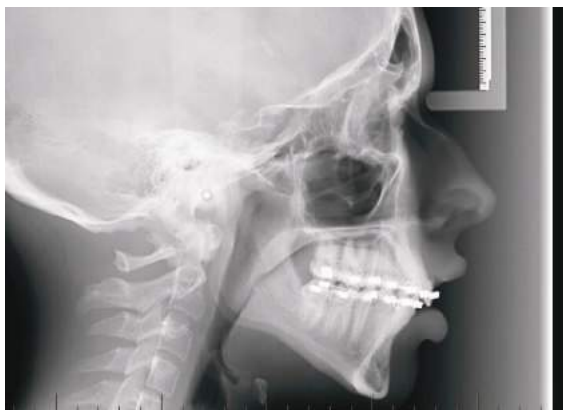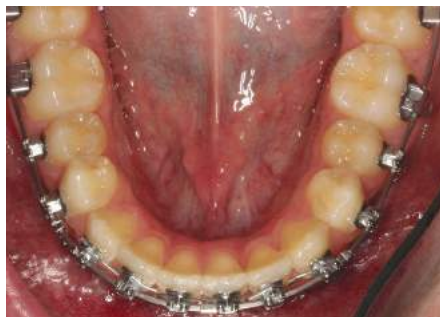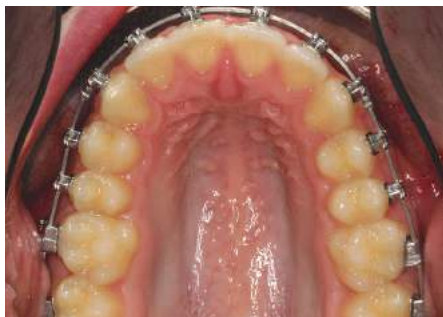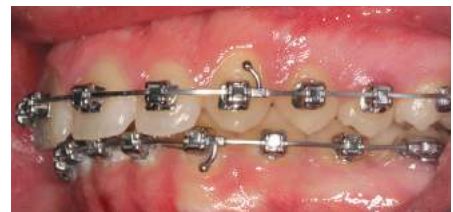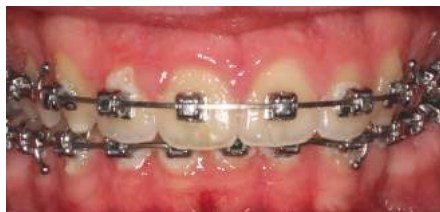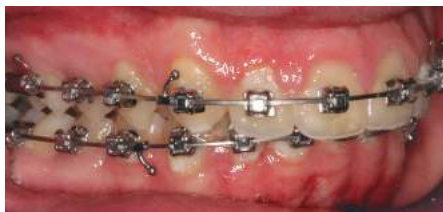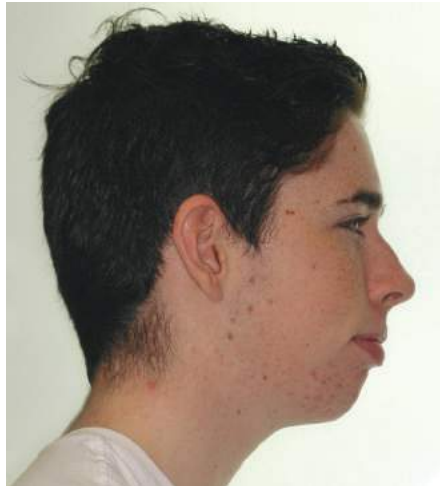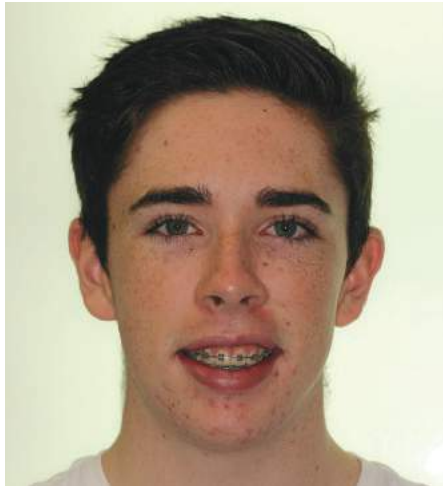 Appointment photos featured in this case study

Pretreatment

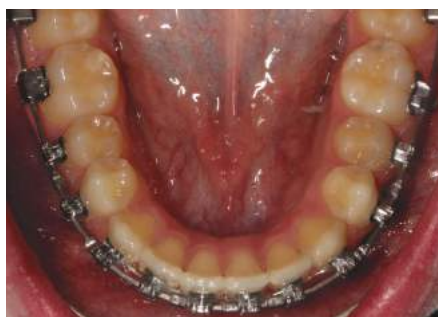
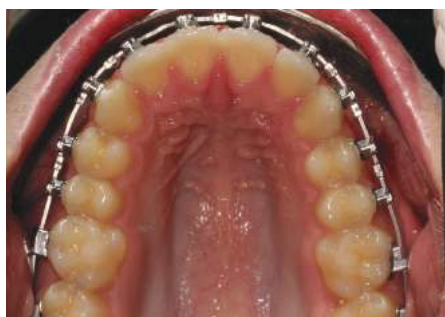
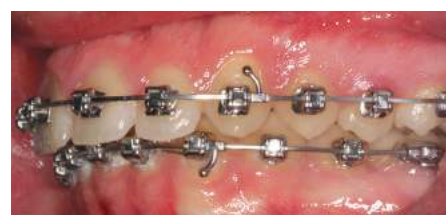
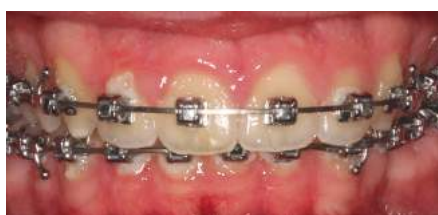
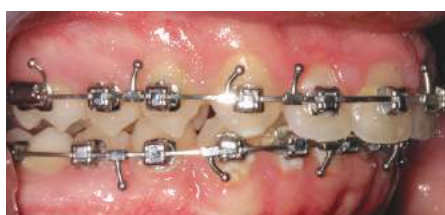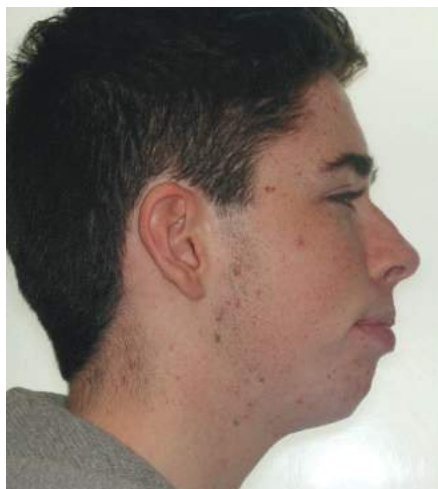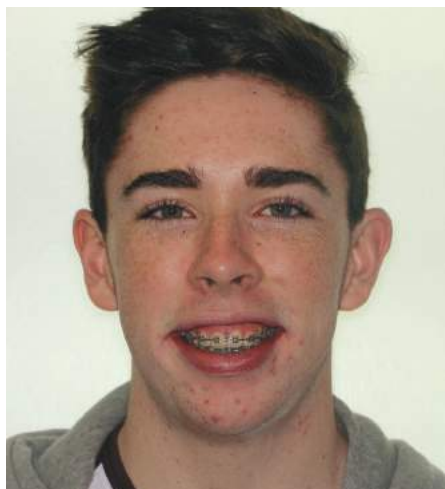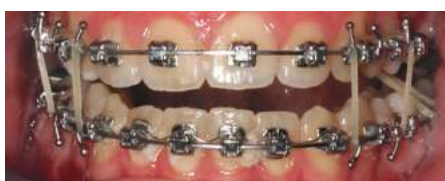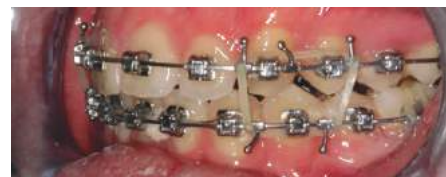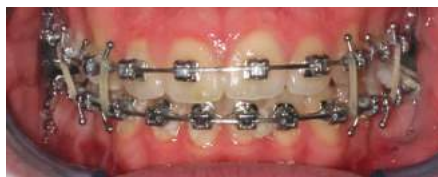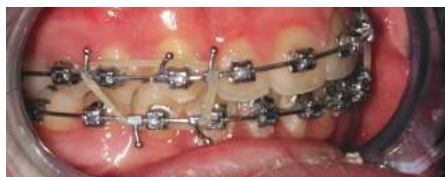Appointment 9, 56 weeks



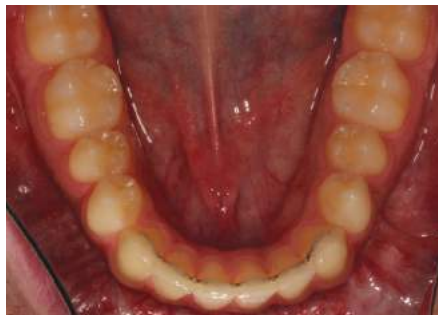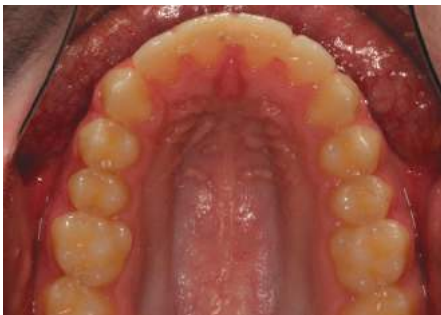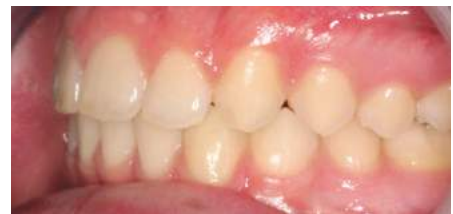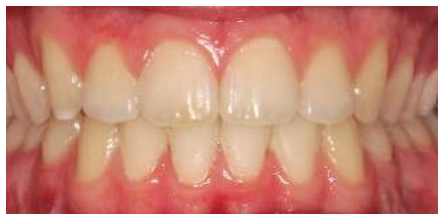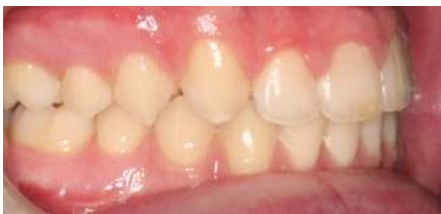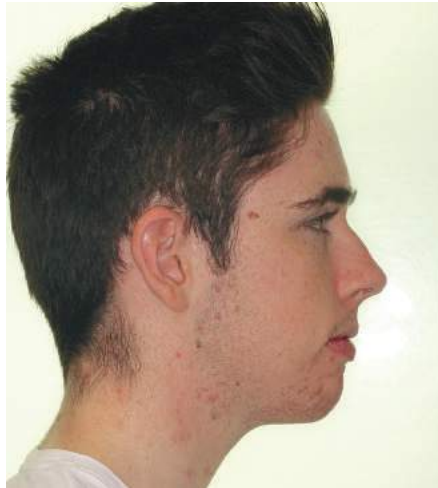**Appointment 13, 74 weeks, pre-surgery visit**



**Appointment 16, 82 weeks**



Final, 89 weeks





## Finishing

- No rebonds
- No Torque adjustments
- 1 very small offset bend between 11,21
- Simple post-surgical elastics
- Expanded upper wire to ensure transverse was ideal

## Treatment Discussion

This was a routine Class II single jaw surgical case. I used Insignia because I use it for every F/F braces case I start.

Insignia is particularly good for surgical cases as it ensures early and accurate arch coordination, to the extent to which the pre-surgical neuromuscular environment permits. It also ensures rapid completion of arch coordination in the new, post-surgical neuromuscular environment.

Customized torque removed the need for third order adjustments.

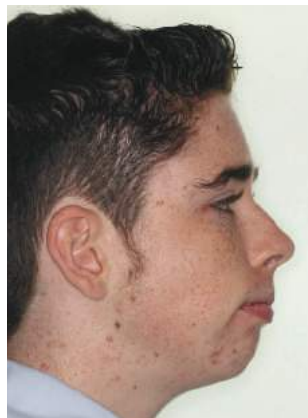
Treatment was slightly lengthened as the original surgeon was unavailable when surgery was required.

The Approver set-up incorporated over expansion of the maxillary posterior teeth to ensure the transverse dimension was adequate at the time of surgery.

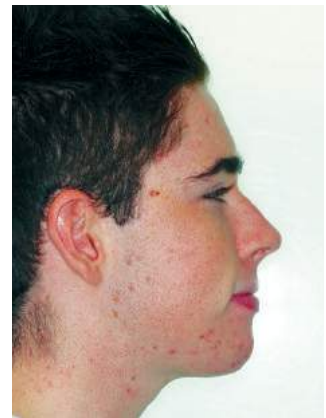## What I Would Do Differently Today

The main thing I would do differently is ensure the setup involved more uprighting or buccal crown torque in the posterior segments to help broaden Aiden's smile some more. Whilst we achieved an excellent result, his smile would have looked better with some more expansion. It is likely we have given him a more stable outcome with the current set up, so it really comes down to doctor preference.

Pre-treatment



Post-treatment



**Dr. Ashley Smith, Toowoomba, QLD, Australia**

**Patient: Minnie**

### Pretreatment Diagnosis

Minnie is a 13 year old female with a dolichofacial, skeletal III growth pattern with a severely crowded maxilla. Her mandible is in a normal position with good arch shape and size. Upper lip is slightly flat with severely crowded 13 and 23. Minnie has good size and shape to her teeth, so there will be no need to veneer. I suggested two treatment plan options:

1. Extract 15 and 25, align upper and lower with fixed appliances and treat with a surgical maxilla impaction and advancement.
2. Avoid orthognathic surgery, align and develop with Damon mechanics and treat the open bite with TAD supported intrusion of the upper posteriors.

We agreed to treat without surgery if possible.

### Treatment Plan Objectives

Treat non-extraction using Insignia SL. Develop the upper arch using Damon style mechanics slowly opening the space for alignment of the 13, 23 with open coil spring.

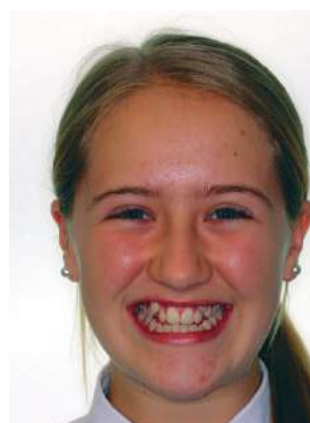Insignia design must show the lower molars not moving mesial or distal and the upper incisors need to extrude and align to a good overjet and overbite.

The T2 occlusion will need to show heavy contact on the incisors and no contact on the molars. The upper archwire plan will need to be positioned high on the 11, 21 at about 6.5 mm.

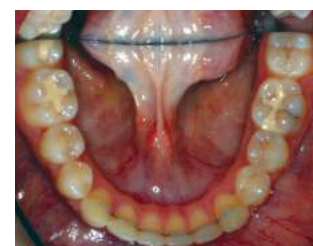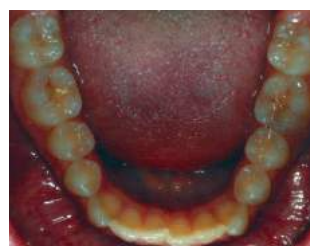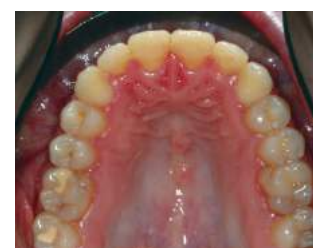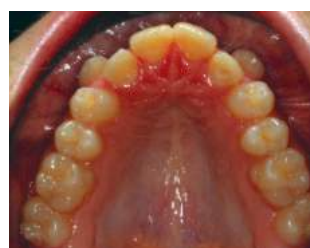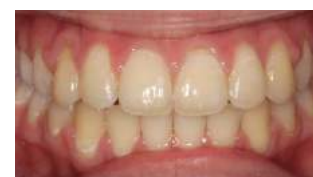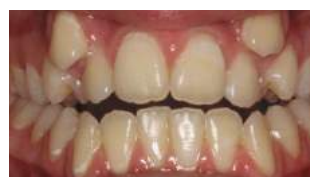Once she was aligned to the .021 x .025 TMAs upper and lower, fit TADs to intrude the upper posteriors.

**Appliance Used:** Insignia SL

Initial



Final





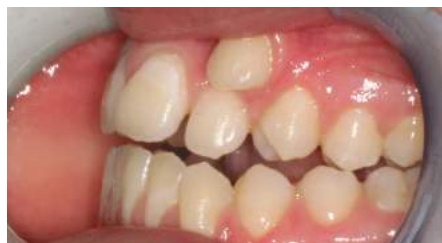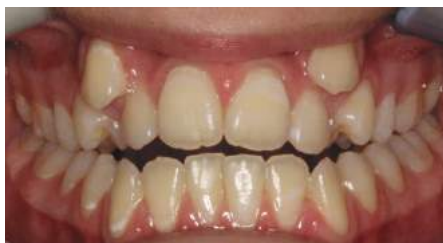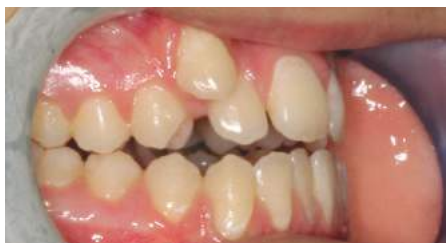## Treatment Sequence

Appointment	Archwire	Notes
<b>1</b>	<b>U:</b> .014 Damon CuNi-Ti* <b>L:</b> .014 Damon CuNi-Ti*	Bonding
<b>2</b> 10 weeks	<b>U:</b> .014 Damon CuNi-Ti* <b>L:</b> .014 Damon CuNi-Ti*	Wire trim only
<b>3</b> 15 weeks	<b>U:</b> .018 CuNi-Ti <b>L:</b> .014 x .025 CuNi-Ti	
<b>4</b> 23 weeks	<b>U:</b> .016 x .025 CuNi-Ti <b>L:</b> .018 x .025 CuNi-Ti	
<b>5</b> 28 weeks	<b>U:</b> .018 x .025 CuNi-Ti <b>L:</b> .021 x .025 35° CuNi-Ti	
<b>6</b> 32 weeks	<b>U:</b> .021 x .025 35° CuNi-Ti <b>L:</b> .021 x .025 TMA	Tie back Upper 3-3 Lower 3-3
<b>7</b> 44 weeks	<b>U:</b> .021 x .025 TMA <b>L:</b> .021 x .025 TMA	
<b>8</b> 53 weeks		
<b>9</b> 58 weeks		Fit TADs and intrusion appliance
<b>11</b> 96 weeks		Started vertical elastics 3/16 4 oz
<b>14</b> 109 weeks		Debonding

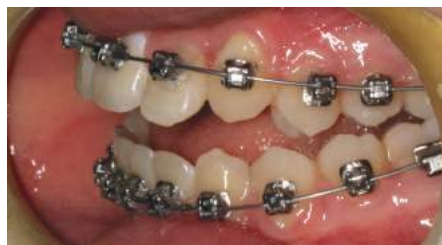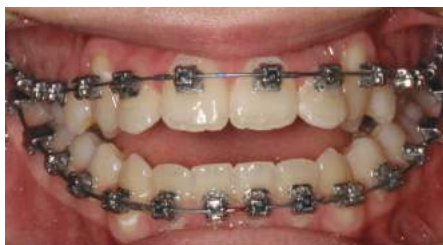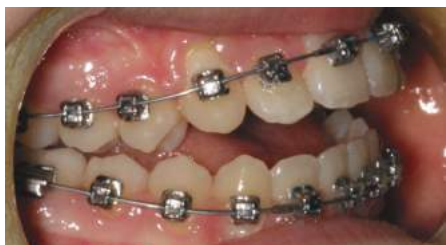\*Stock round wire

 Appointment photos featured in this case study

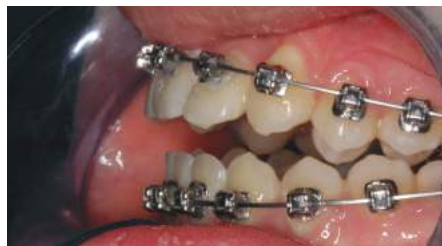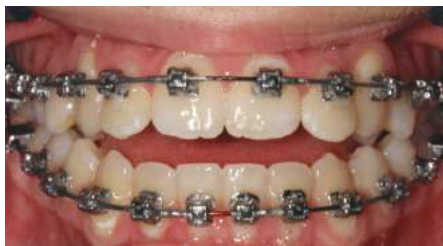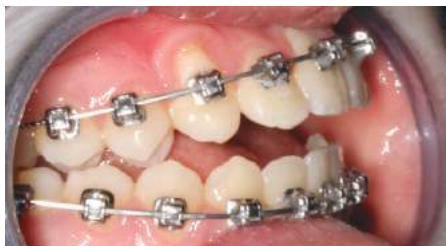**Bonding**



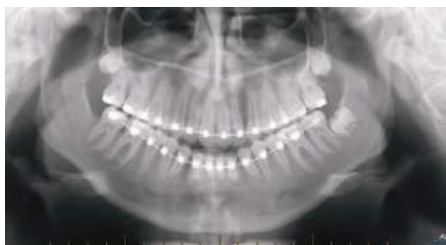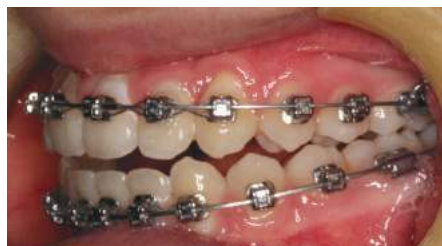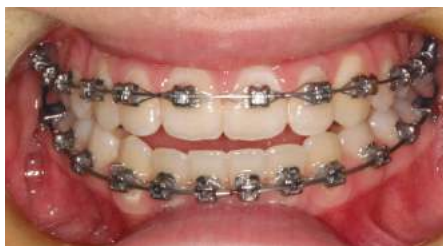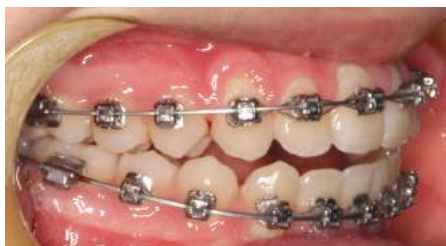**Appointment 3, 15 weeks**



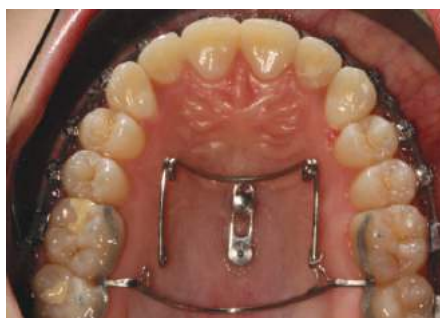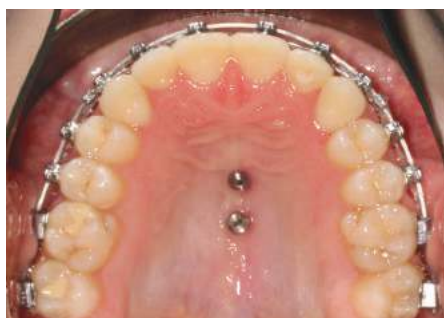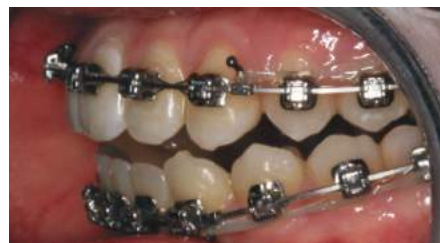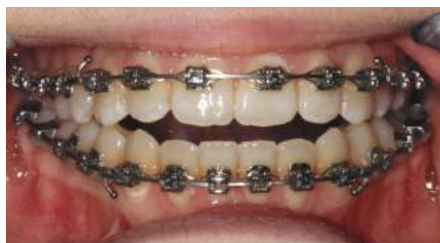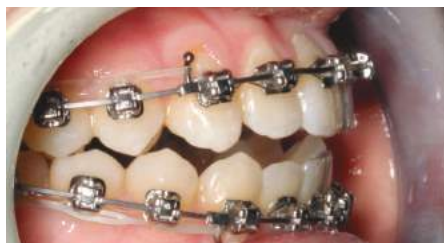**Appointment 5, 28 weeks**



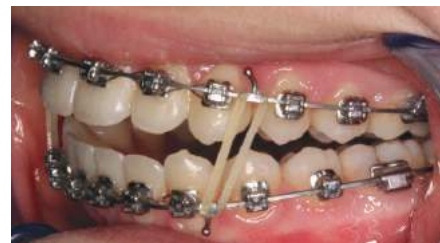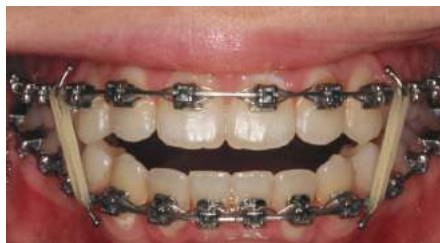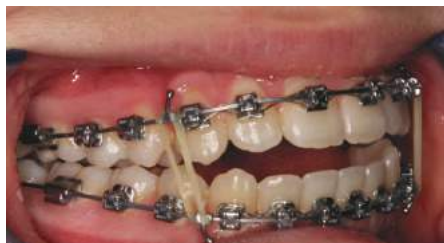**Appointment 7, 44 weeks**



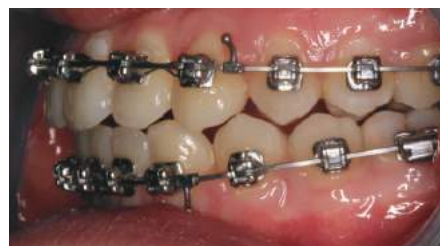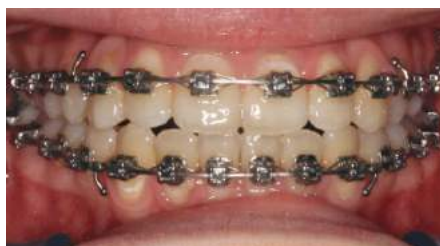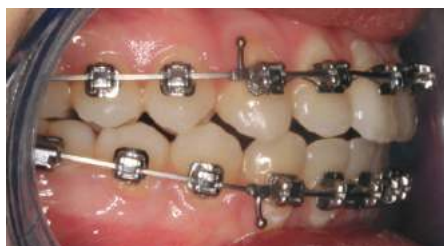**Appointment 9, 58 weeks**



**Appointment 11, 90 weeks**

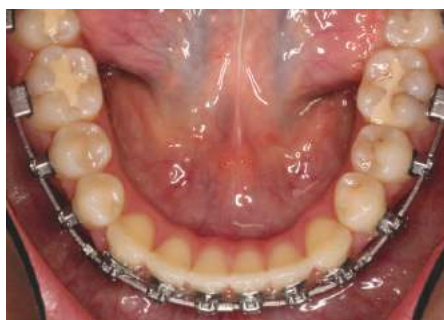
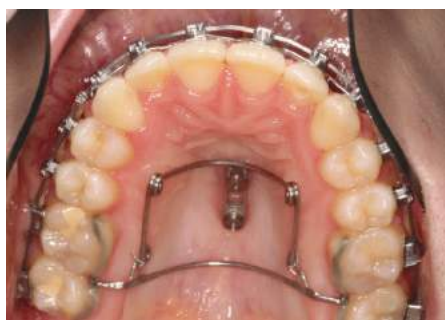
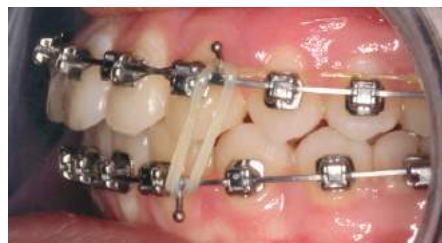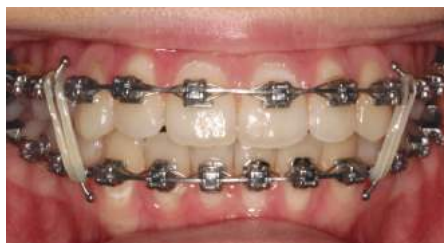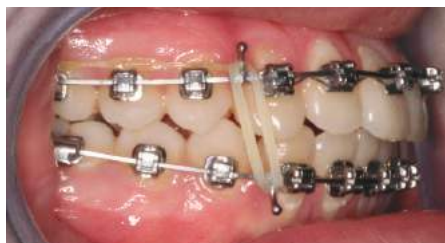**Appointment 12, 96 weeks**

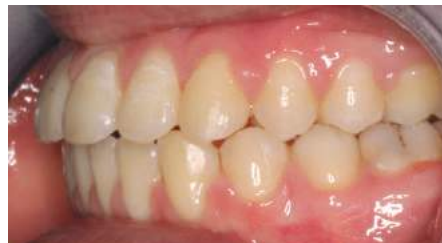
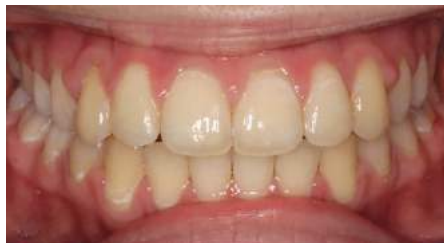
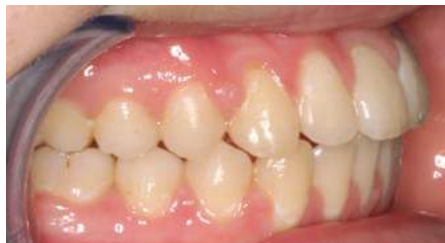

**Appointment 13, 101 weeks**



**Final, 109 weeks**



## Treatment Discussion

All treatment objectives were achieved and the patient was very pleased with her orthodontic result.

It was important to take time in the light round wires and slowly open space to align the 13 and 23. Once we transitioned to the .018 Damon CuNi-Ti, we were able to quickly progress through the Insignia archwires until Minnie was on the .021 x .025 TMA.

The final aesthetic result is very good with the incisors positioned upright with an excellent smile arc.

The incisor proportions and gingival relationships are close to ideal as are the connectors and embrasures.

Minnie's treatment took longer than needed as when she was ready to start the TAD intrusion they delayed until it was made clear that a successful result could only be achieved.

I used the BENIFT-System 11mm and 9mm TADs placed in the suture distal of the third rugae. The "mouse trap" appliance and the bonded TPA were custom made in our practice laboratory.

The excellent torque control was delivered with the Insignia system using torque compensation and choosing .021 x .025 size archwires. It was pleasing to achieve a great aesthetic result for Minnie especially at such an early age. She was finished at age 15 which is no doubt great for her self-esteem.

The retention of any open bite is very important and can be challenging. We placed upper and lower bonded retainers with upper and lower clear retainers worn each night.



**Dr. David Birnie**, Newcastle upon Tyne, United Kingdom

**Patient: Victoria**

### Pretreatment Diagnosis

33-year-old female at the start of treatment, Class II division 2. The patient is concerned about the appearance of her upper front teeth. She had good upper incisor display and a good smile arc.

The #47 had been previously extracted.

### Treatment Plan Objectives

Positive upper incisor crown torque required. Wire plane on FA point. No build-ups.

Lower centreline to right and likely to worsen as #48 moved forward into 4.7 space. Planned TAD Q4 to support anchorage as #48 moved forward. Full closure of #47 space planned.

Molar AP movement: RHS  $\frac{3}{4}$  II and LHS  $\frac{1}{2}$  II. Planned correction by Class II elastics.

Expansion: AP expansion planned to change axial inclination of anterior teeth, to support the lips and to reduce overbite. Principal method of overbite reduction is extrusion of lower posterior buccal segments using anterior bite turbos and short Class II elastics to protect upper incisor display.

No extractions.

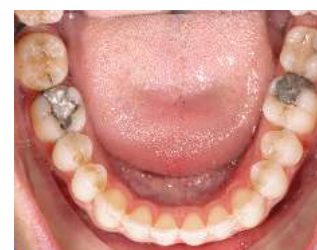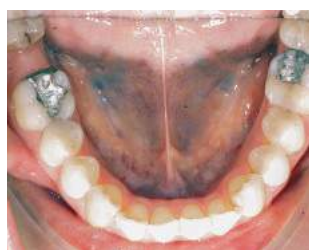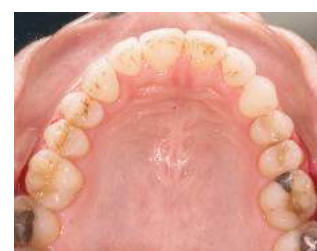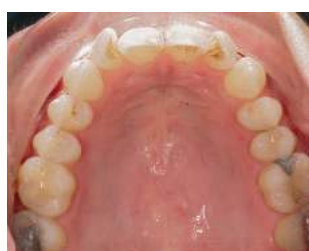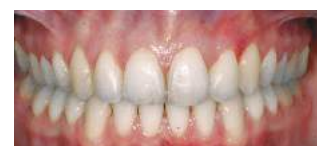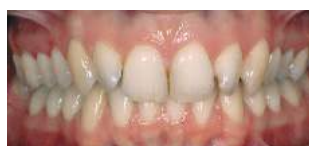Notes to Insignia technician at time of case submission: "Damon set-up, canines 0.5mm above incisors, ensure match of smile arc to curvature of lower lip when smiling. No single jigs please."

**Appliance Used:** Upper Damon Clear 5-5, Lower Insignia SL

Initial



Final



## Treatment Sequence

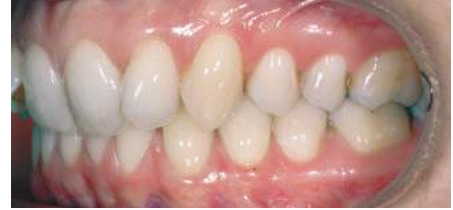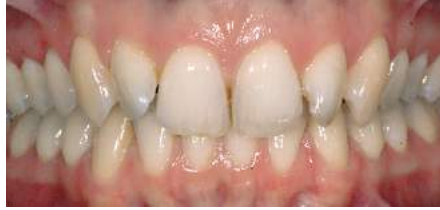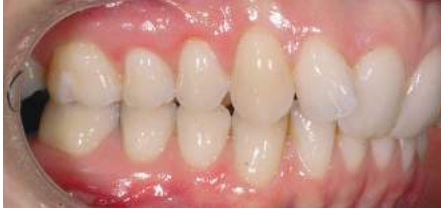Appointment	Archwire	Notes
1	<b>U:</b> .013 Damon CuNi-Ti* <b>L:</b> .013 Damon CuNi-Ti*	Bonding Anterior bite turbos Class II elastics not started to allow patient to get used to fixed appliances
2 Week 4		Oral ulceration Quail 3/16" 2oz short Class II elastics; two each side
3	<b>U:</b> .014 Damon CuNi-Ti* <b>L:</b> .014 Damon CuNi-Ti*	
4	<b>U:</b> .016 Damon CuNi-Ti* <b>L:</b> .016 Damon CuNi-Ti*	
5 Week 16	<b>U:</b> .018 Damon CuNi-Ti* <b>L:</b> .018 Damon CuNi-Ti*	
6	<b>U:</b> .014 x .025 CuNi-Ti <b>L:</b> .014 x .025 CuNi-Ti	
7 24 Wochen	<b>U:</b> .018 x .025 Copper NiTi® <b>L:</b> .018 x .025 Copper NiTi®	Upper power chain Moose 5/6" 6oz long Class II elastics
8		Change upper power chain Protract #48
9	<b>U:</b> .016 x .025 SS <b>L:</b> .016 x .025 SS	Moose 5/6" 6oz long Class II elastics Change upper and lower power chain and powerchain Q4 to protract #48
10		Change upper and lower power chain
11	<b>U:</b> .019 x .025 SS	
12		Change upper and lower power chain IPR #12 #22 to eliminate small black triangles

Appointment	Archwire	Notes
<b>13</b> Week 46		12mm NiTi closing coil Q4 Derotate #48 with double cable mechanics
<b>14</b>		Space closed in Q4 Stop Class II as both buccal segments class I Change upper and lower power chain
<b>15</b>	<b>U:</b> .017 x .025 L-F TMA <b>L:</b> .018 Damon CuNi-Ti*	Rebond #48 to normal tube position, Rebond #43 and #33 to correct small rotations Intrude #11, #12 with step-up bend
<b>16</b> Week 61	<b>U:</b> .019 x .025 L-F TMA <b>L:</b> .017 x .025 L-F TMA	Increase step-up bend to Intrude #11, #12 further
<b>17</b>		Intrude #12 Change upper and lower power chain
<b>18</b>		Finishing bends: intrude #12, step-out mesial edge of #12 labially, extrude #23
<b>19</b> Week 71		Debonding Retention: Upper Bond-A-Braid #12 to #22 Lower single stand SS wire bonded #33 to #43 Upper and lower full arch pressure formed retainers nights only

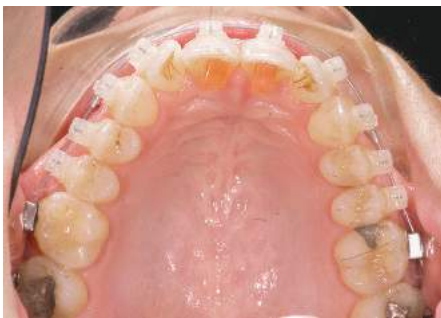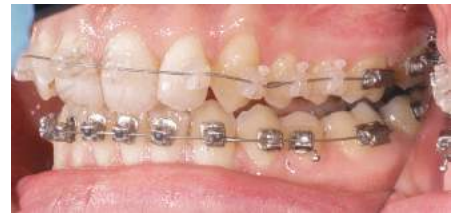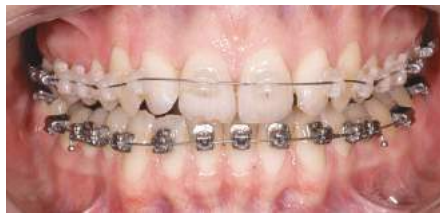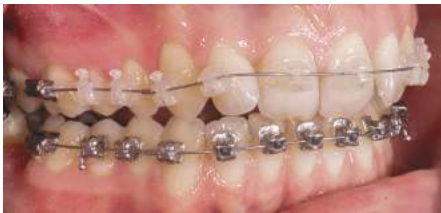\*Stock round wire

 Appointment photos featured in this case study

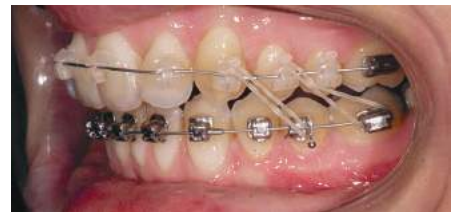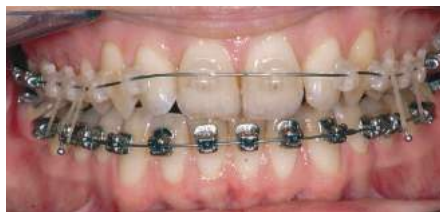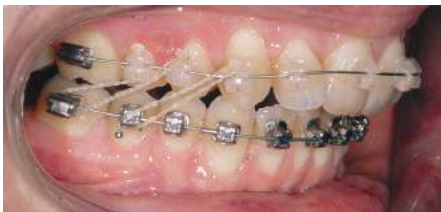**Initial**



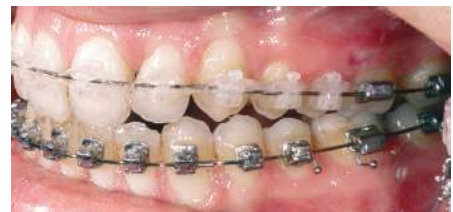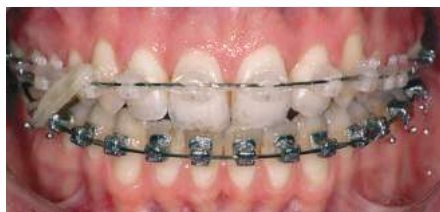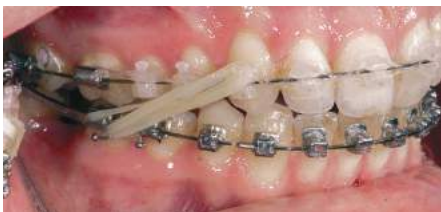**Appointment 1, 1 Week**



**Appointment 2, 4 Week**

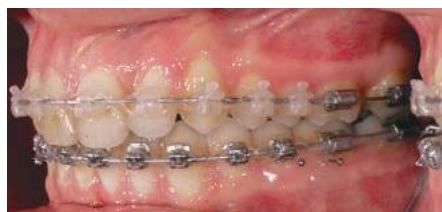
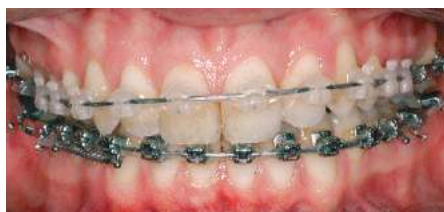
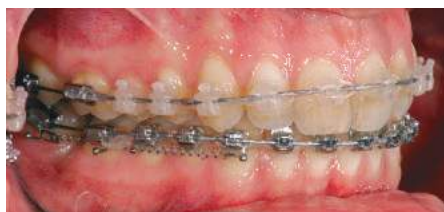**Appointment 7, 24 Week**

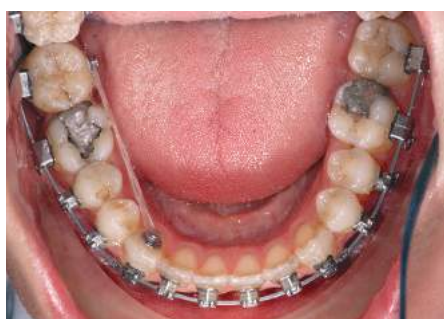
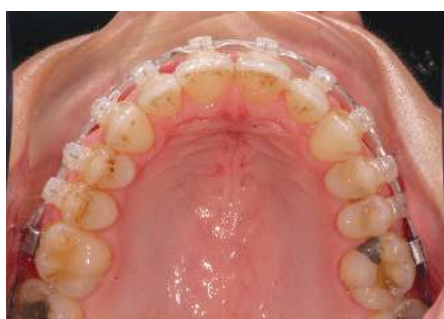
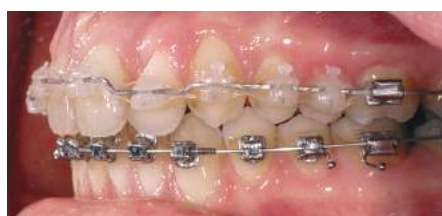
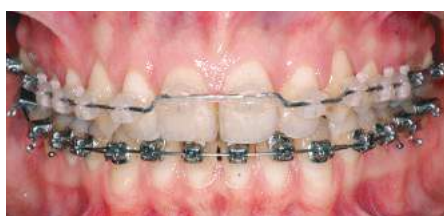
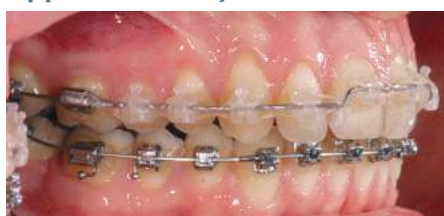**Appointment 13, 46 Week**

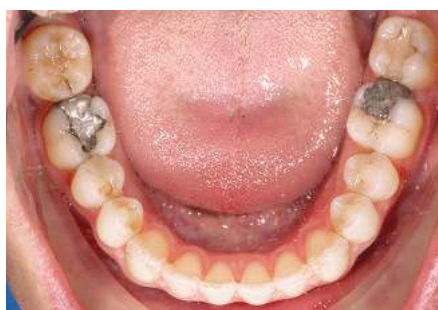
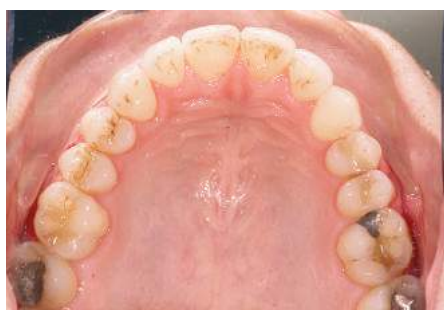
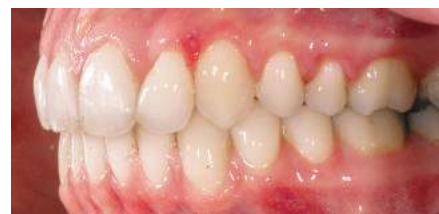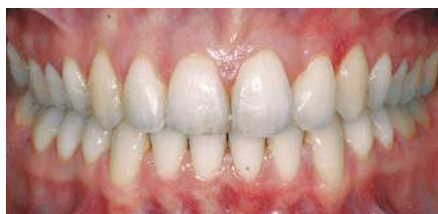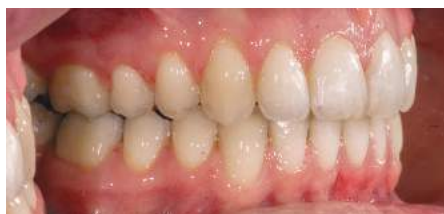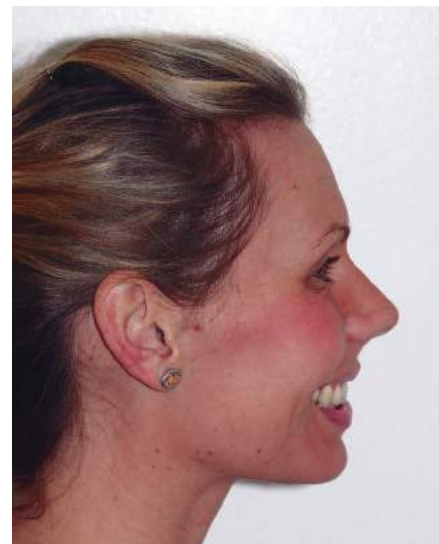**Appointment 16, 61 Week**





Final, 71 weeks



## Treatment Discussion

Treatment objectives achieved and the patient was very happy with the result.

I requested a smile arc that was too deep; it can be difficult translating what is seen on a large computer screen into clinical reality. There is no normative data on smile arcs and smile arcs that are between 50% and 75% of the curvature of the lower lip usually look aesthetically pleasing.

The incisor display remained unchanged as planned and the relationships between adjacent anterior teeth improved. Dentsply Triad Gel, a visible light cure acrylic was used for the anterior bite turbos to prevent damage to the lower incisor edges as it is much softer than enamel.

The patient had easy access to the clinic and so once initial alignment was achieved, treatment intervals were shortened to decrease treatment time. As the patient was an adult, arch wire progression was deliberately slow and gentle.

The closure of the #47 space and improving the Class II relationship on the right was technically challenging. In practice, the use of a TAD was not required. Initially, #48 was bonded manually with the tube tilted slightly gingivally at the mesial end in order to maintain root parallelism as the space was closed. Once the space was closed, the #48 tube was rebounded in the planned position using the spare jig. Some rotation of 47 occurred during space closure causing increased resistance to sliding (Rs) as well as poor rotational alignment of the tooth; the countermeasure for this was the use of double cable mechanics to ensure optimal alignment between the molar tube, the archwire and the direction of tooth movement.

The patient was very cooperative and compliant with outstanding oral hygiene throughout treatment.

Treatment time was good at 71 weeks (1 year and 5 months) although lengthened by the need to close the #47 space.

## What I Would Do Differently Today

Pay more attention to design of smile arc in Insignia Approver (Ai). Use the grid function to help quantify the depth of the smile arc.

Start double cable mechanics to protract 48 as soon as space closure was started. Focusing on identifying areas of increased Rs and then implementing countermeasures to reduce this shortens treatment time.

**Dr. David González Zamora, Madrid, Spain**  
**Patient: Lorena**

**Pretreatment Diagnosis**

Adult female, mesofacial, skeletal class I, open bite.

Patient suffered from frequent headaches.

**Treatment Plan Objectives**

Close her open bite while maintaining vertical relationship of upper anterior incisors.

Treatment plan notes submitted with this case:

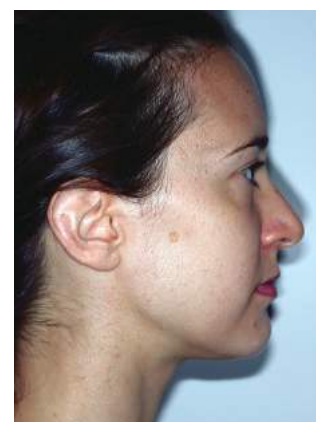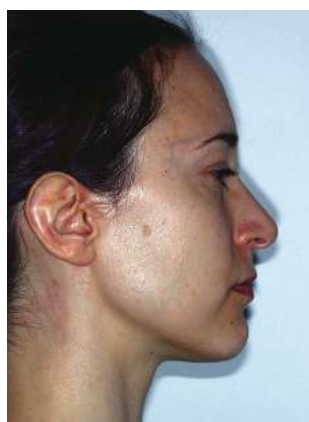- Insignia Archform
- Laterals should be shorter than centrals
- Align marginal ridges
- 3mm of overbite
- Expansion through molars and premolars
- IPR between premolars

**Verwendete Apparatur:** Insignia SL

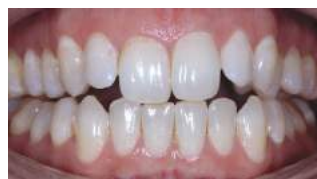**Initial**



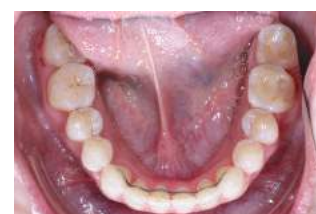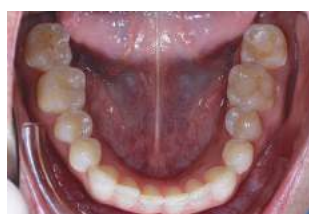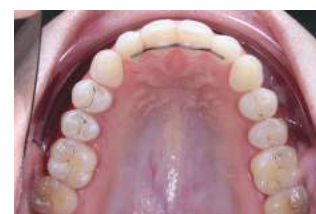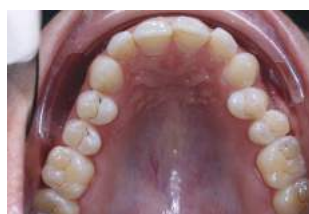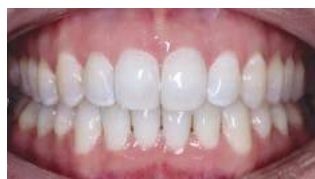**Final**



**Initial**



**Final**



## Treatment Sequence

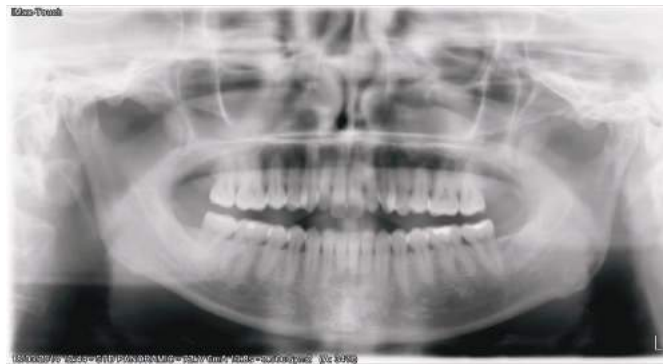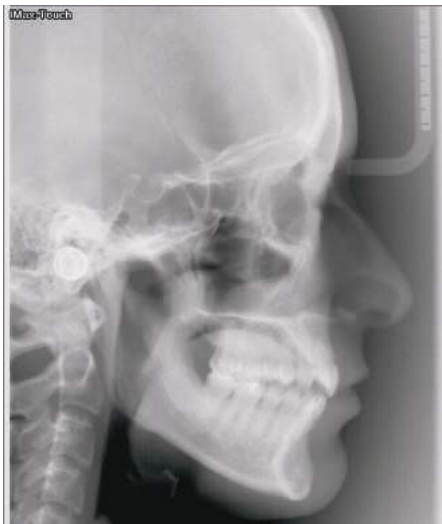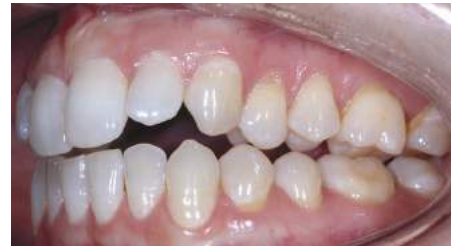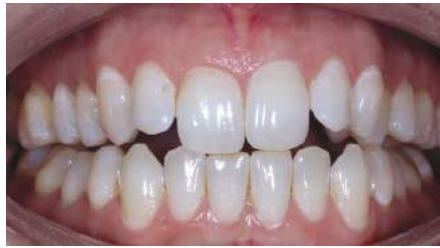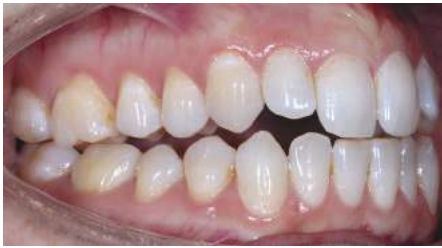Appointment	Archwire	Notes
<b>1</b>	<b>U:</b> .014 Damon CuNi-Ti* <b>L:</b> .014 Damon CuNi-Ti*	Bonding Triangle Chipmunk 1/8" 3.5 Oz
<b>2</b> 10 Wochen	<b>U:</b> .014 x .025 CuNi-Ti <b>L:</b> .014 x .025 CuNi-Ti	Triangle Chipmunk 1/8" 3.5 Oz
<b>3</b> 22 Wochen	<b>U:</b> .018 x .025 CuNi-Ti <b>L:</b> .018 x .025 CuNi-Ti	Triangle Chipmunk 1/8" 3.5 Oz
<b>4</b> 34 Wochen	<b>U:</b> .018 x .025 CuNi-Ti <b>L:</b> .018 x .025 CuNi-Ti	Triangle Chipmunk 1/8" 3.5 Oz Rebond 27
<b>5</b> 38 Wochen	<b>U:</b> .019 x .025 SS <b>L:</b> .019 x .025 SS	Anterior box Moose 5/16" 6 Oz
<b>6</b> 46 Wochen	<b>U:</b> .019 x .025 SS <b>L:</b> .019 x .025 SS	Triangle Chipmunk 1/8" 3.5 Oz Anterior box Moose 5/16" 6 Oz Elinks to close spaces
<b>7</b> 57 Wochen	<b>U:</b> .019 x .025 SS <b>L:</b> .019 x .025 SS	Triangle Chipmunk 1/8" 3.5 Oz Anterior box Moose 5/16" 6 Oz IPR 2-2 Elastic chain 3-3 Occlusal adjustment
<b>8</b> 62 Wochen	<b>U:</b> .019 x .025 SS <b>L:</b> .019 x .025 SS	Debonding Fix retainer 2-2, 3-3 Occlusal splint

\*Stock round wire

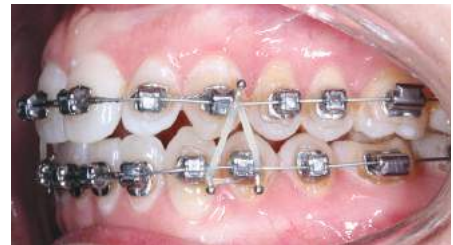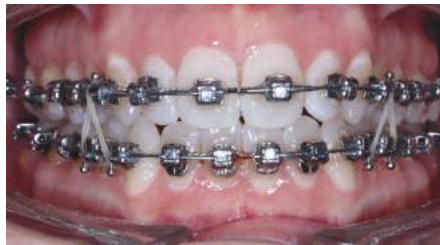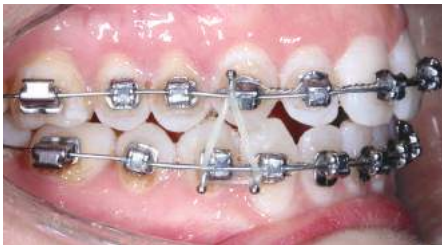 Appointment photos featured in this case study



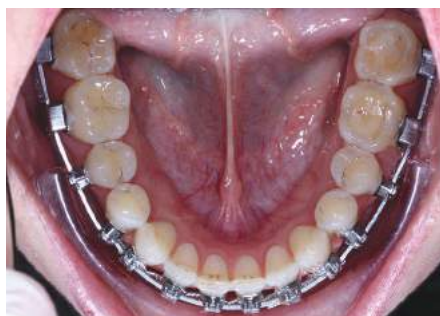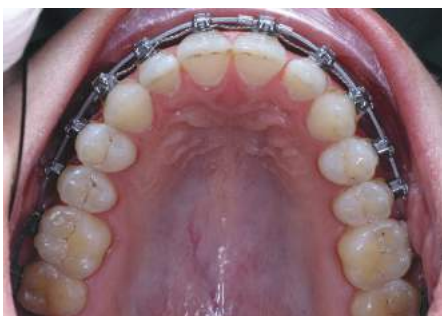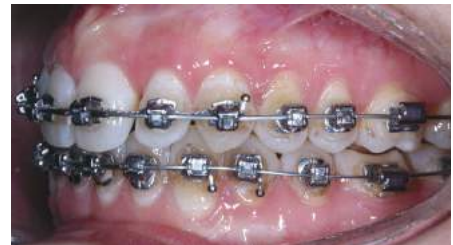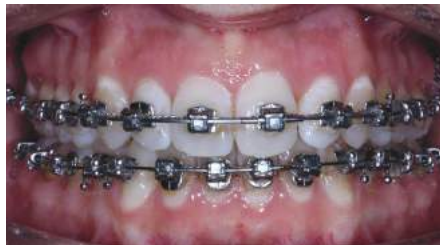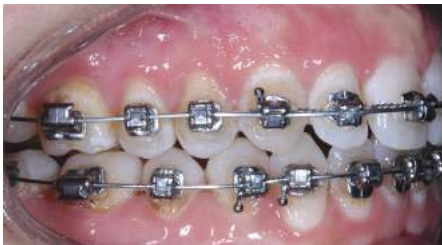**Initial**



**Appointment 3, 2 weeks**

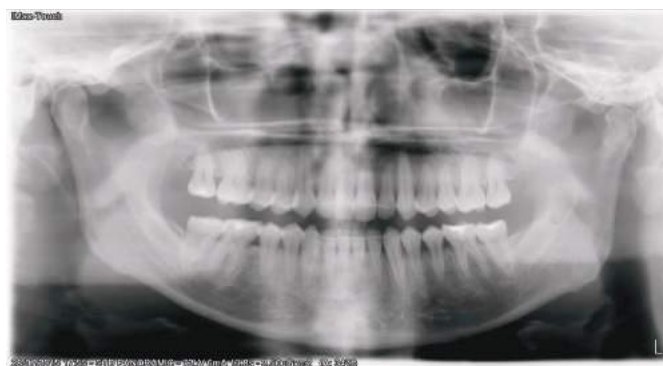
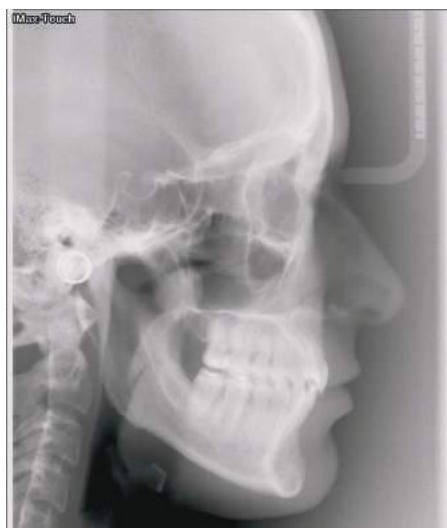
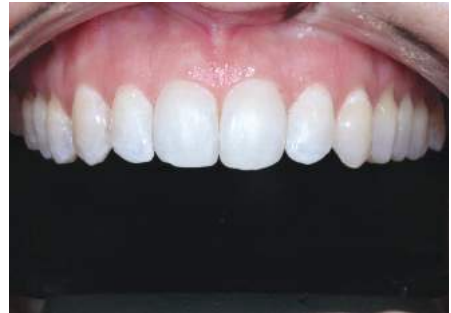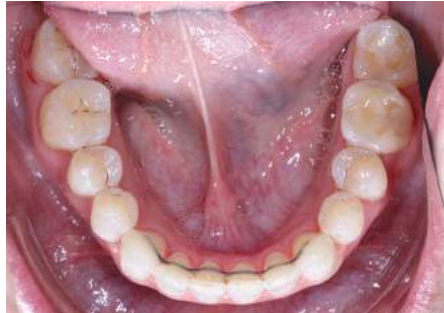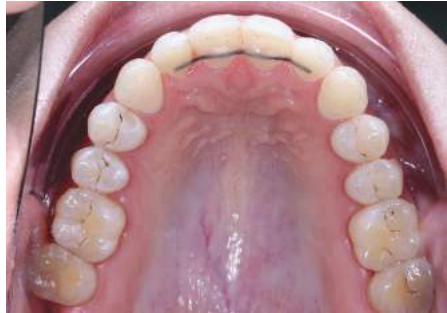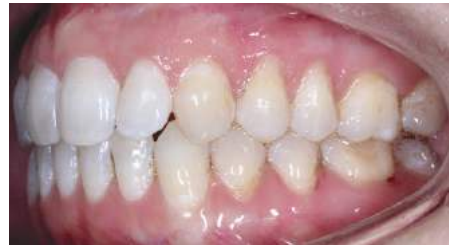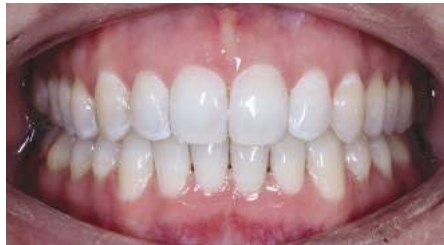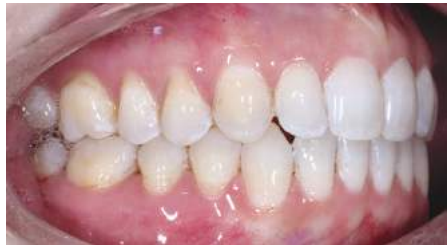**Appointment 7, 57 weeks**





Final, 62 weeks



## Treatment Discussion

The patient had a complete open bite due to the habit of atypical swallowing.

To perform a bite closure, it is necessary to achieve perfect alignment and leveling of the teeth as well as obtaining accurate torque. Only then can we face the upper and lower occlusal planes. In addition, the two arches have been expanded at premolars and molars. The key to making a bite close quickly and easily is applying forces mesial to the arcade center of resistance, just so get a rotation of both occlusal planes.

Despite using an extrusive mechanics with previous elastics, you can see in the photo finish smile that the relationship of the upper incisors has not worsened, thanks to the relative position of the brackets at the time of cementation. The patient also followed a rehabilitation treatment neuromuscular speech pathologist, to ensure the future stability of the case.

## Finishing Notes

No debonds, no wire bends. Just occlusal adjustment.

**Dr. David González Zamora, Madrid, Spain**

**Dr. César Colmenero Ruiz - Maxillofacial Surgeon**

**Patient: Natalia**

**Pretreatment Diagnosis**

Adult female, dolichofacial, skeletal Class III, jaw deviation to the right, maxilla compression, open bite, anterior and posterior crossbite.

Patient had an upper midline deviation to the right. 14 and 24 absence.

**Treatment Plan Objectives**

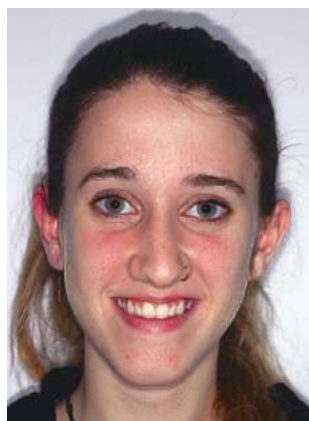
Maxillary advancement with expansion and mandibular setback. Class II molar. Class I canine.

Treatment plan notes submitted with this case:

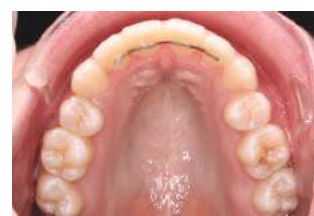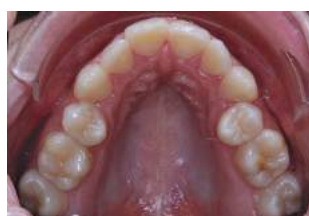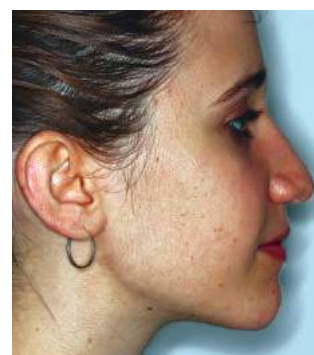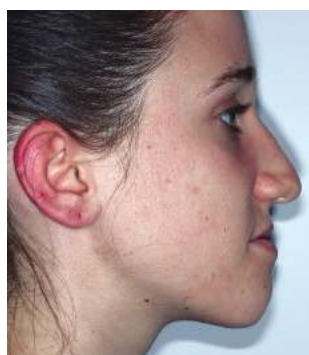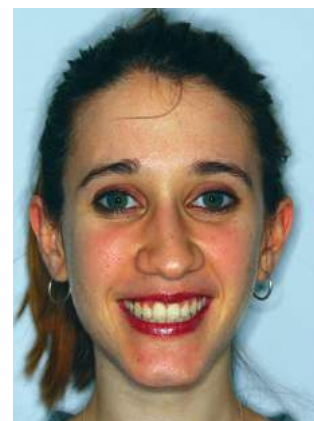- Insignia Archform
- Laterals should be shorter than centrals
- Align marginal ridges
- 3mm of overbite
- Expansion between canines, premolars and molars
- IPR 3-3

**Appliance Used:** Insignia SL

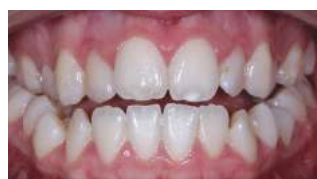**Initial**



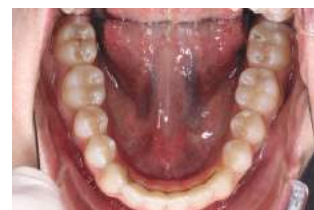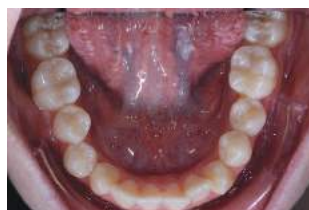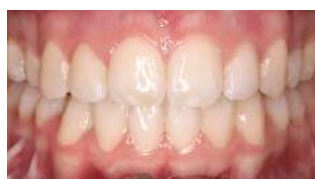**Final**



**Initial**



**Final**



## Treatment Sequence

Appointment	Archwire	Notes
<b>1</b>	<b>U:</b> .014 Damon CuNi-Ti* <b>L:</b> .014 Damon CuNi-Ti*	Button on 43 to derotate
<b>2</b> Week 4	<b>U:</b> .014 Damon CuNi-Ti* <b>L:</b> .014 Damon CuNi-Ti*	
<b>3</b> Week 22	<b>U:</b> .014 Damon CuNi-Ti* <b>L:</b> .014 Damon CuNi-Ti*	Bonding of 43
<b>4</b> Week 26	<b>U:</b> .014 x .025 CuNi-Ti <b>L:</b> .014 x .025 CuNi-Ti	
<b>5</b> Week 35	<b>U:</b> .018 x .025 CuNi-Ti <b>L:</b> .018 x .025 CuNi-Ti	
<b>6</b> Week 40	<b>U:</b> .018 x .025 CuNi-Ti <b>L:</b> .019 x .025 SS	Class II elastics Impala 3/16" 3.5 Oz
<b>7</b> Week 45	<b>U:</b> .019 x .025 SS <b>L:</b> .019 x .025 SS	Class II elastics Impala 3/16" 3.5 Oz
<b>9</b> Week 49	<b>U:</b> .019 x .025 SS <b>L:</b> .019 x .025 SS	Presurgery Study
<b>10</b> Week 55	<b>U:</b> .019 x .025 SS <b>L:</b> .019 x .025 SS	Adapt Surgery splints
<b>11</b> Week 57	<b>U:</b> .019 x .025 SS <b>L:</b> .019 x .025 SS	Surgery
<b>12</b> Week 58	<b>U:</b> .018 x .025 CuNi-Ti <b>L:</b> .019 x .025 SS	Triangle elastics Chipmunk 1/8" 3.5 Oz
<b>13</b> Week 60	<b>U:</b> .019 x .025 SS <b>L:</b> .019 x .025 SS	Triangle elastics Chipmunk 1/8" 3.5 Oz

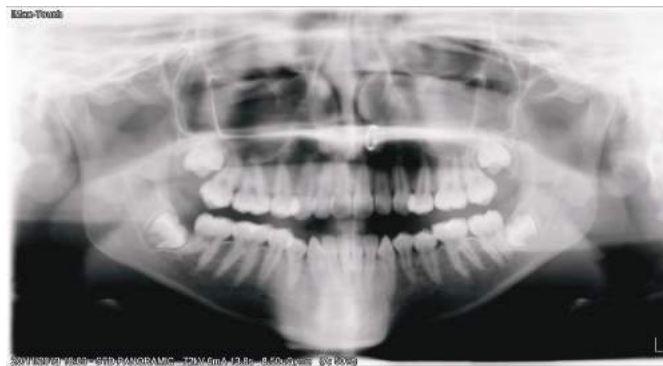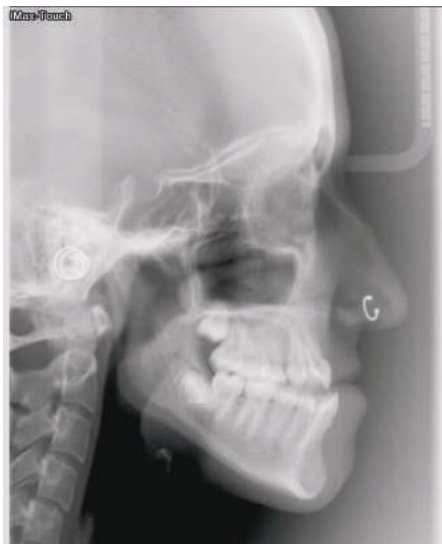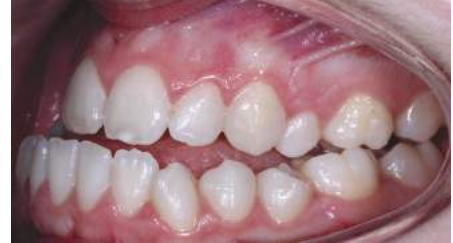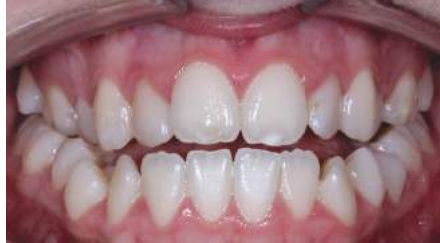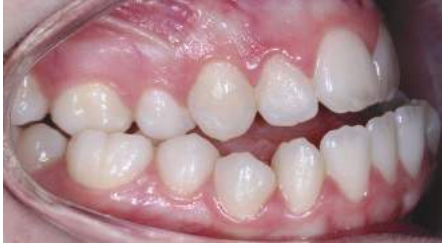Appointment	Archwire	Notes
<b>14</b> Week 63	<b>U:</b> .019 x .025 TMA <b>L:</b> .019 x .025 TMA®	Triangle elastics Chipmunk 1/8" 3.5 Oz Anterior box elastics Moose 5/16" 6 Oz
<b>15</b> Week 69	<b>U:</b> .019 x .025 TMA® <b>L:</b> .019 x .025 TMA®	Triangle elastics Chipmunk 1/8" 3.5 Oz Anterior box elastics Moose 5/16" 6 Oz
<b>16</b> Week 73	<b>U:</b> .019 x .025 TMA® <b>L:</b> .019 x .025 TMA®	Triangle elastics Chipmunk 1/8" 3.5 Oz Anterior box elastics Moose 5/16" 6 Oz
<b>17</b> Week 81	<b>U:</b> .019 x .025 TMA® <b>L:</b> .019 x .025 TMA®	Triangle elastics Chipmunk 1/8" 3.5 Oz Anterior box elastics Moose 5/16" 6 Oz
<b>18</b> Week 85		Debond Fix retainers

\*Stock round wire

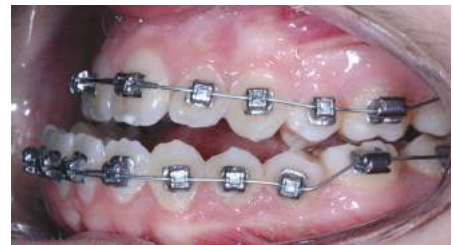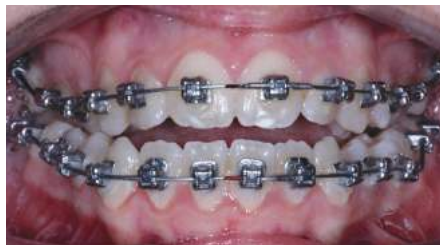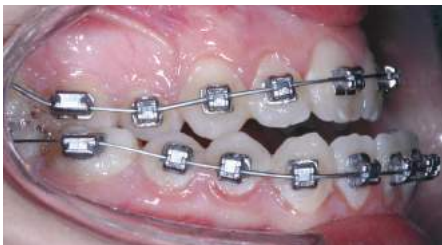 Appointment photos featured in this case study



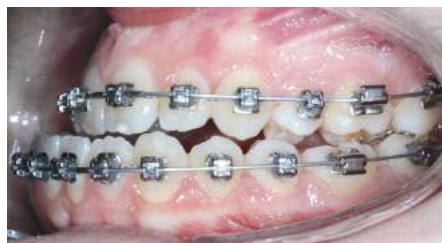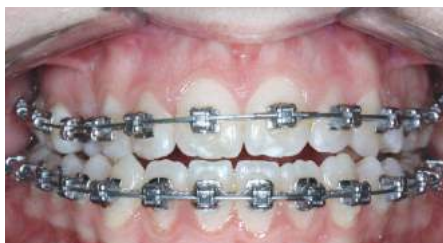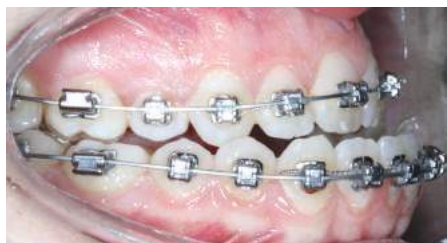**Initial**



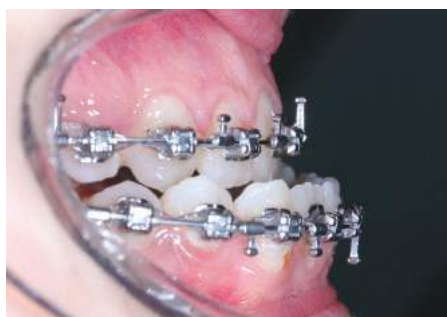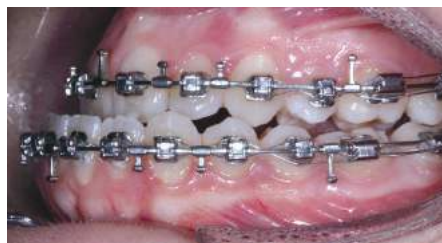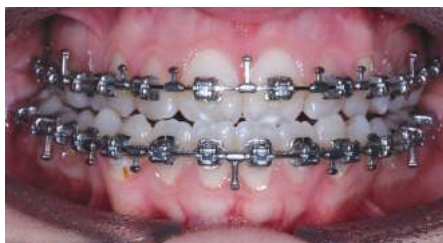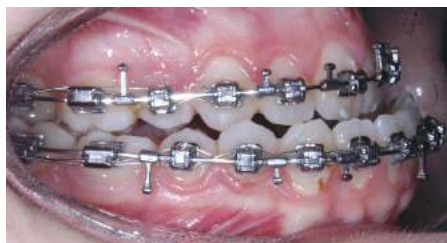**Appointment 4, 26 weeks**



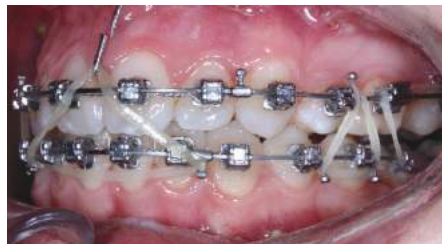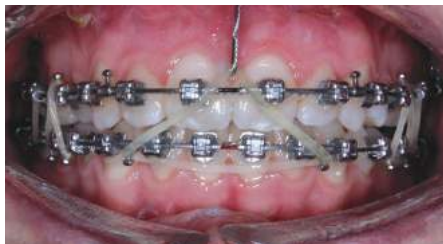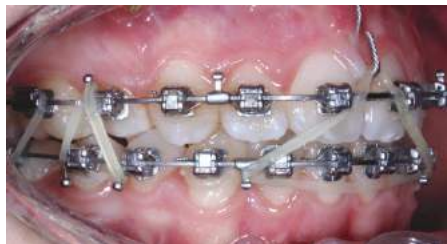**Appointment 7, 45 weeks**



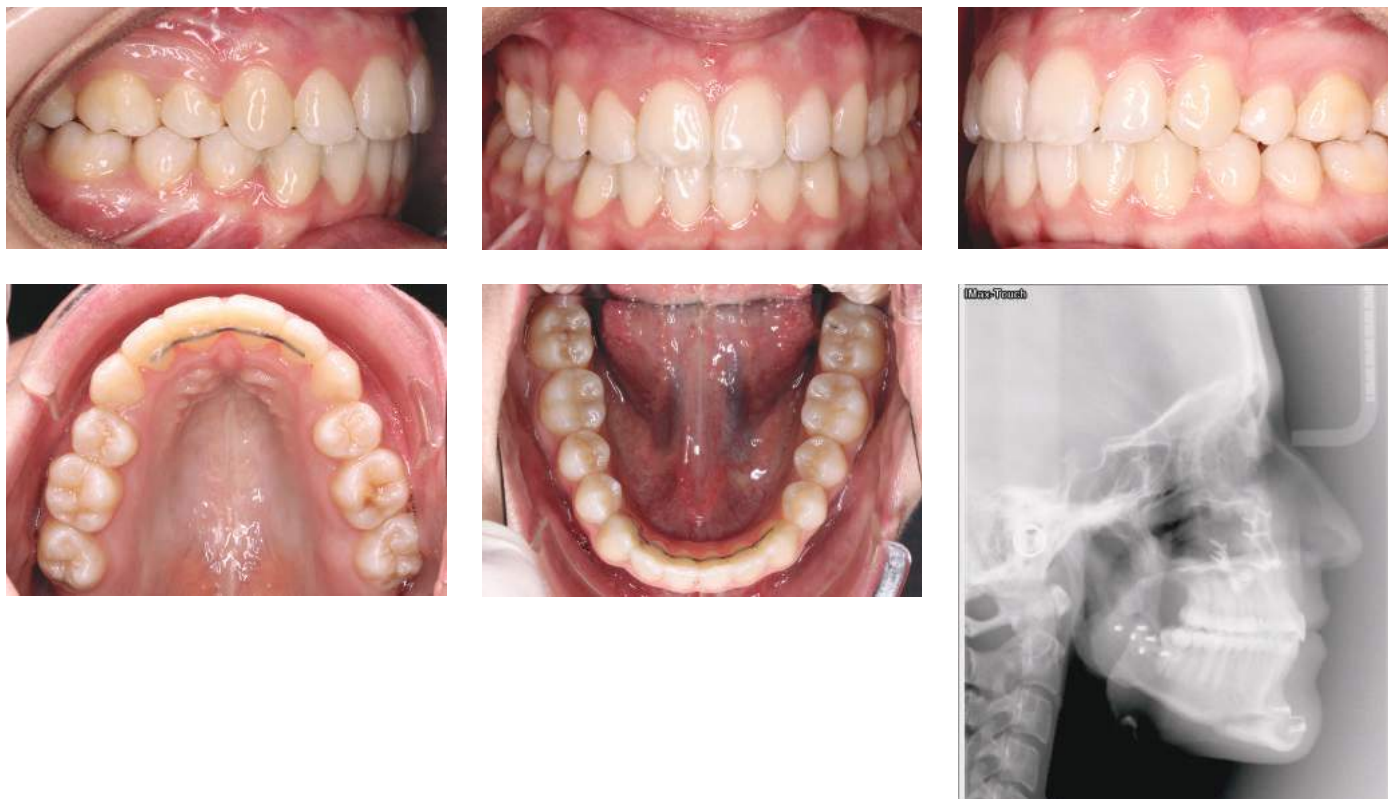**Appointment 10, 55 weeks**



**Appointment 13, 60 weeks**



**Final, 85 weeks**



### **Treatment Discussion**

The patient had a skeletal Class III, with complete crossbite and open bite. Insignia SL treatment system is ideal in surgical cases, as we work from the beginning with the archform adapted to the patient's skeletal biotype. In addition, adjusting the postsurgical occlusion is much better because the accuracy cementation and expression of torques, so we can finish with less elastics biomechanics.



**Dr. Jamie Reynolds, Novi, MI**

**Patient: Firas**

### Pretreatment Diagnosis

A 23-year-old male presented with a Class I molar relationship, mild overjet, constricted upper and lower arches that resulted in excessive buccal corridors, and an AOB tendency with slightly flared upper incisors, which exhibited moderate incisal edge irregularity. The patient exhibited a good smile arc and mild gingival recession anteriorly and in the buccal segments. Facially, his profile was slightly convex with a vertical growth tendency and a slightly recessive chin. His lips were quite full, but with an obtuse vermillion display.

### Treatment Plan Objectives

The focus of the 3D Approver-assisted treatment plan was to use the Insignia™ Advanced Smile Design™ custom bracket and wire system to address the issues outlined in the diagnosis while protecting the patient's satisfactory attributes. Arch development would be accomplished through a progression of light round to full-size custom rectangular wires in a passive self-ligating lumen with a patient-specific prescription. The patient preferred aesthetic brackets for the upper incisors. When the case was bonded, Insignia did not offer custom aesthetic SL brackets so I direct-bonded stock Damon Clear brackets upper 3 to 3 with the variable torque options matched as closely as possible to the custom torques the Insignia setup indicated. I direct-bonded the stock brackets according to the positions indicated on the Approver software. The variable torque stock brackets would be employed to detorque the upper incisors while protecting or enhancing the smile arc.

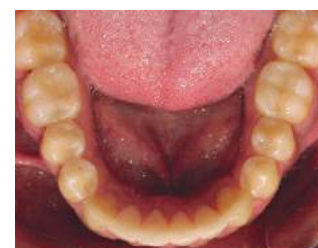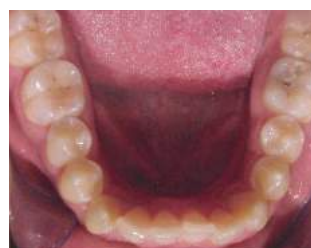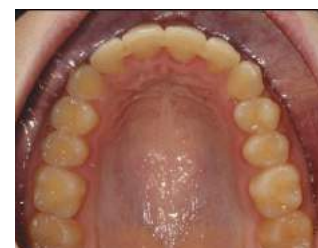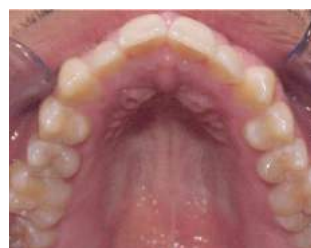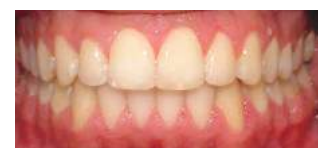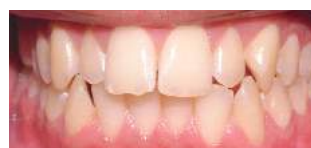Today, Insignia offers aesthetic brackets, which now its placement is driven by software and provides jigs for precise bracket bonding.

Had this option been available for this case and I had bonded them using the accompanying

Behandlungsbeginn



Behandlungsende



placement guides, the bracket repositions would likely not have been needed, which would have saved at least one treatment visit.

The case required considerable central incisor tooth reshaping. Teeth can be reshaped either before treatment or during/after treatment. It is my preference to begin reshaping at the “pano/repo” appointment (when we routinely take a panograph to evaluate root positions and reposition brackets accordingly), finalizing the final anatomy detailing at debonding (Figure 3). I have found better aesthetic results with this approach than attempting to reshape the incisors before treatment when the teeth are not yet aligned. Insignia offers an IPR tool that imparts important guidance in planning and visualizing such protocols, but doctors needn’t be concerned that such tools—or the system as a whole—will ever replace our knowledge, skills and clinical experience.

#### **Appliance Used:**

Upper: Damon Clear 3-3, Insignia SL45 Lower:  
Insignia SL

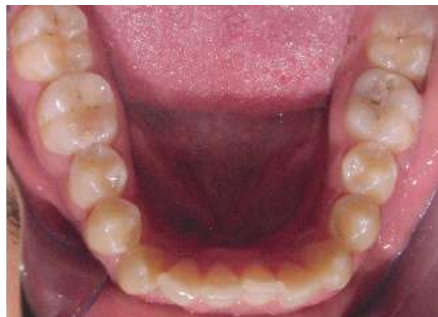
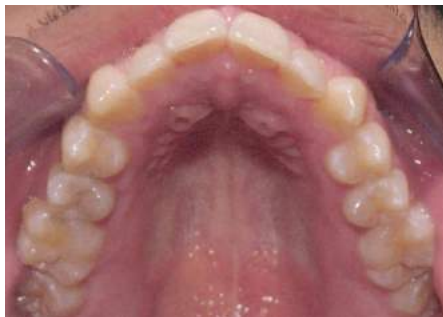
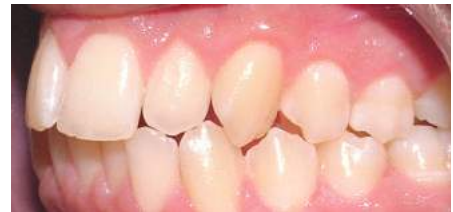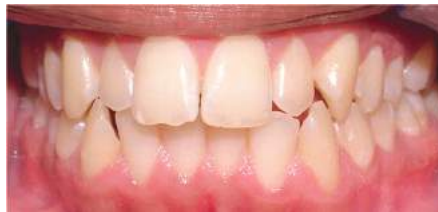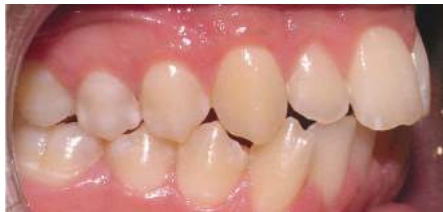## Treatment Sequence

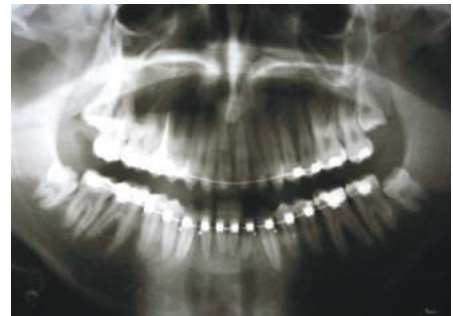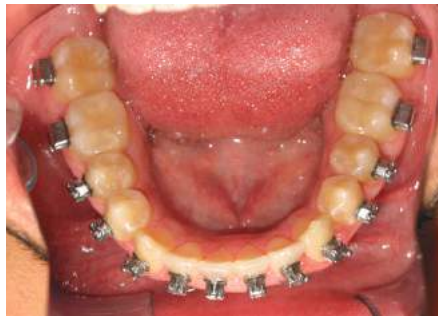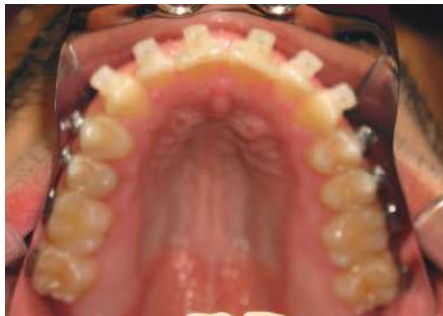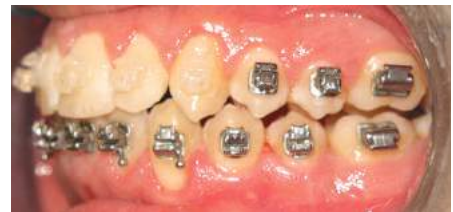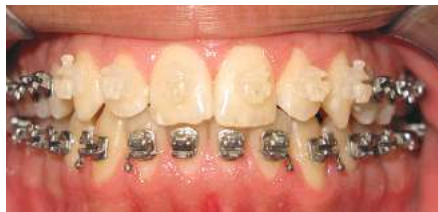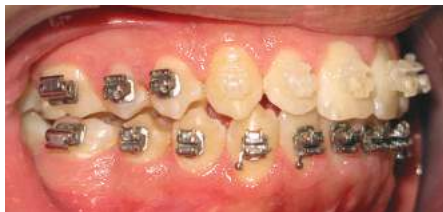Appointment	Archwire	Notes
1	<b>OK:</b> .014 Damon CuNi-Ti* <b>UK:</b> .014 Damon CuNi-Ti*	To address the anterior open bite tendency, anterior box elastics (5/16" 2 oz.) were begun at bonding and continued for 6.5 months. The use of early light elastics (never more than 2 oz. to start) has been a protocol quite beneficial in addressing various intra-arch discrepancies (both A/P and vertical). Certainly, there is greater compliance during the initial stages of treatment. Various elastics configurations (CL II, buccal box, anterior etc..) continued until the end of treatment with no elastics heavier than 3.5 oz.
2 11 weeks	<b>OK:</b> .014 x .025 CuNi-Ti <b>UK:</b> .014 x .025 CuNi-Tii	
3 20 weeks	<b>OK:</b> .018 x .025 CuNi-Ti <b>UK:</b> .018 x .025 CuNi-Ti	
4 29 weeks	<b>OK:</b> .018 CuNi-Ti <b>UK:</b> .019 x .025 TMA	Panograph/Root Assessment: At this juncture (when the .018" x .025" custom Copper Ni-Ti wires have been engaged 4 to 6 weeks), we routinely take a panograph to assess root positions. In this case, I had to reposition 3 brackets, which we the Clear brackets i direct-bonded. At this point, the transverse development of the arch had improved and the upper incisors had detorqued slightly from this expansion. The upper incisor inclination and posterior bite would further improve with the expression of the torque in the finishing wires.
5 33 weeks	<b>OK:</b> .016 x .025 CuNi-Ti <b>UK:</b> .018 x .025 TMA	
6 39 weeks	<b>OK:</b> .019 x .025 TMA <b>UK:</b> .019 x .025 TMA	
7 50 weeks		Debond

 Appointment photos featured in this case study

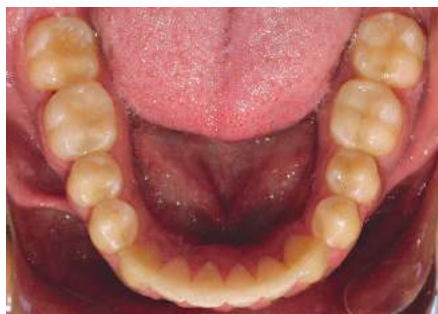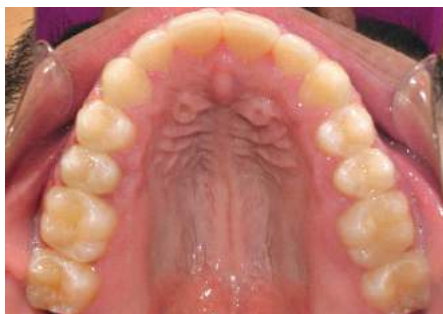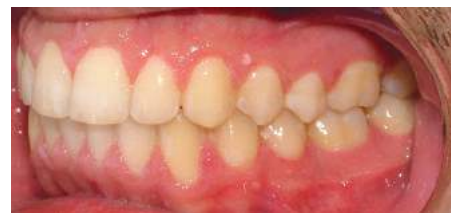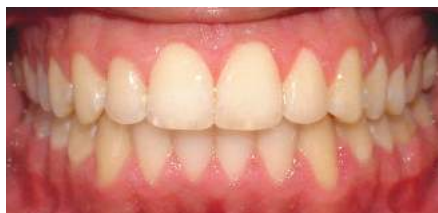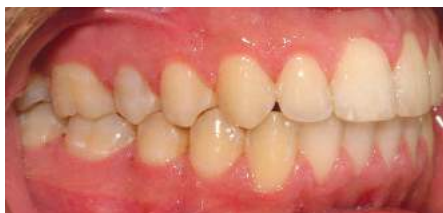**Bonding**



**4th Appointment, 29 weeks**



**Final Appointment, 50 weeks**



## Treatment Discussion

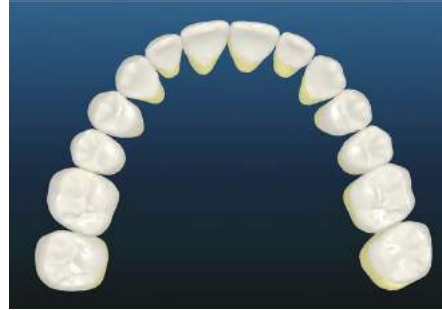The case treated to an excellent finish quite efficiently in 11.5 months in nine treatment appointments (including bonding and debonding) and two emergency visits.

As mentioned previously, careful tooth reshaping of the incisal edges, embrasures and interproximal surfaces added significantly to the final aesthetic result. We chose not to accentuate the smile arc because it would have been at the cost of increasing gingival display, which would not have suited this patient's aesthetics.

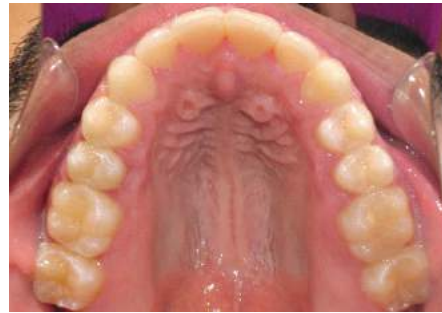One of the beauties of using Insignia is that the buccal occlusion will not be iatrogenically disrupted by malpositioned brackets or one-size-fits-all torques that move teeth unfavorably, requiring multiple adjustments late in treatment.

The planned Approver setup for the arch shape very clearly matches the final result. Being able to visualize such results at the beginning of treatment greatly assists in communicating the treatment goals and expectations to patients. As competition for acquiring orthodontic patients increases, orthodontists will need to continue to distinguish themselves both in the quality of and in the speed at which orthodontic cases are finished. The transition to digital orthodontics will allow orthodontists to continue to be the providers of choice for high-quality orthodontic treatment.

## Approver Setup



## Final Result



# Contributors

**Dr. Ashley Smith**

Toowoomba City, Australia

**Barbara Brunner**

B2 Studio

**Dr. Christopher Turnock**

Toowoomba City, Australia

**Dr. David Birnie**

Newcastle upon Tyne, United Kingdom

**Dr. David González Zamora**

Madrid, Spain

**Dr. David Sarver**

Birmingham, Alabama

**Dr. Jamie Reynolds**

Novi, Michigan

**Dr. Jeff Kozlowski**

New London, Connecticut

**Dr. Sonia Palleck**

Woodstock, Ontario





**Ormco**<sup>™</sup>

Ormco B.V.  
Basicweg 20  
3821 BR Amersfoort  
The Netherlands  
[www.ormcoeurope.com](http://www.ormcoeurope.com)

©2017 Ormco Corporation

762-6580